



## Inferior ST-Segment Elevation Myocardial Infarction with First-Degree Atrioventricular Block: A Case Report and Literature Review

Aditya Doni Pradana<sup>1\*</sup>, Jarot Widodo<sup>2</sup>

<sup>1</sup>Department of Emergency Services, Kendal Islamic Hospital, Kendal, Central Java, Indonesia

<sup>2</sup>Department of Cardiology and Vascular Medicine, Kendal Islamic Hospital, Kendal, Central Java, Indonesia

### ARTICLE INFO

\*Corresponding author  
email:  
aditya.doni.p@gmail.com

address:  
Jalan A.R. Rahmah No. 17 Kendal,  
Kabupaten Kendal,  
Jawa Tengah 51355

Keywords:  
Inferior STEMI; first-degree AV Block; reperfusion;  
fibrinolytic

Manuscript submitted: March 16, 2020  
Revised and accepted: May 10, 2020

### ABSTRACT

**Background:** Atrioventricular (AV) block complicating acute inferior wall ST-elevation myocardial infarction (STEMI) is known to be associated with poor outcomes and increased rate of mortality.

**Case Report:** We present the case of a 69-year old male patient, active smoker, presented to the emergency department due to syncope 2 hours prior admission. He reported symptoms while farming with sudden onset of diaphoresis, mild dizziness and breathlessness followed by loss of consciousness for several minutes. Blood pressure was 79/55 mmHg, respiratory rate was 23, pulse was 46 bpm. Electrocardiogram showed inferior wall STEMI with first-degree AV block. Laboratory data revealed significantly marked increased of CK-MB 82,5 U/L. STEMI protocol and fibrinolytic therapy has been done. The mechanisms of AV block and its spontaneous resolution in the setting of acute inferior wall STEMI are discussed. Attention is drawn to the patient due to our hospital categorized as incapable cathlab sub-district hospital.

**Discussion:** Clinical signs and examination suggested that this patient had a first-degree AV block complicating inferior wall STEMI on admission and fulfill the criteria of successful reperfusion 30 minutes following fibrinolytic therapy. Immediately after fibrinolysis, breathlessness was relieved, ST-T segment was reduced, spontaneous resolution of first-degree AV block occurred, and absence of Q-wave formation.

**Conclusion:** Immediate reperfusion therapy is the core management of STEMI patient, including fibrinolytic therapy. Signs of successful therapy could be seen in this case and also relieved of the complication associated with STEMI. We found it as an incidence not much reported and thus reporting the case herewith.

### INTISARI

**Pendahuluan:** Infark miokard dengan elevasi segmen ST akut (STEMI) dinding inferior dengan blok atrioventrikular (AV) dikaitkan dengan luaran buruk dan peningkatan kematian.

**Laporan Kasus:** Dalam laporan kasus ini disajikan kasus seorang laki-laki 69 tahun, perokok aktif, datang ke instalasi gawat darurat (IGD) karena sinkop 2 jam sebelum admisi. Pasien melaporkan gejala-gejala pada saat bertani dengan keluar keringat dingin mendadak, pusing, dan kesulitan bernapas diikuti dengan kehilangan kesadaran selama beberapa menit. Tekanan darah didapatkan 79/55 mmHg, laju napas 23, denyut nadi 46 kali per menit. Elektrokardiogram (EKG) didapatkan adanya STEMI inferior dengan AV blok derajat satu. Pemeriksaan laboratorium didapatkan kenaikan signifikan CK-MB 82,5 U/L. Protokol STEMI dan terapi fibrinolitik telah dilakukan pada

pasien ini. Mekanisme AV blok dan resolusi spontan pada kasus STEMI inferior akan dibahas. Pembahasan berfokus pada pasien dengan perawatan di rumah sakit tanpa fasilitas cathlab.

*Diskusi:* Tanda klinis dan hasil pemeriksaan didapatkan bahwa pasien memiliki STEMI inferior disertai komplikasi AV blok derajat satu pada saat admisi dan setelah dilakukan protokol STEMI, reperfusi sukses didapatkan 30 menit pasca fibrinolitik. Setelah fibrinolitik, didapatkan keluhan rasa sulit bernapas hilang, elevasi segmen ST-T berkurang, resolusi spontan AV blok derajat satu, dan tidak terbentuknya gelombang Q patologis.

*Kesimpulan:* Terapi reperfusi segera adalah manajemen inti dari kasus STEMI, termasuk terapi fibrinolitik. Tanda keberhasilan terapi dapat terlihat pada kasus ini dan hilangnya komplikasi berkaitan dengan STEMI. Kami menemukan bahwa kejadian tersebut tidak banyak dilaporkan oleh sebab itu kami laporkan.

## Introduction

Atrioventricular (AV) block complicating acute myocardial infarction (AMI) is known to be associated with poor outcomes and increased rate of mortality.<sup>1,2</sup> The incidence of AV block in AMI patients are varied approximately 2-20% depending on the anatomical location of the AMIs investigated.<sup>3,4</sup> Several studies found that inferior AMI are more prone to develop AV block (1st, 2nd, and 3rd degree) compared with patients with anterior AMI.<sup>4,5</sup> ST-segment elevation myocardial infarction (STEMI) also increased risk of AV block development compared with non-STEMI.<sup>1</sup>

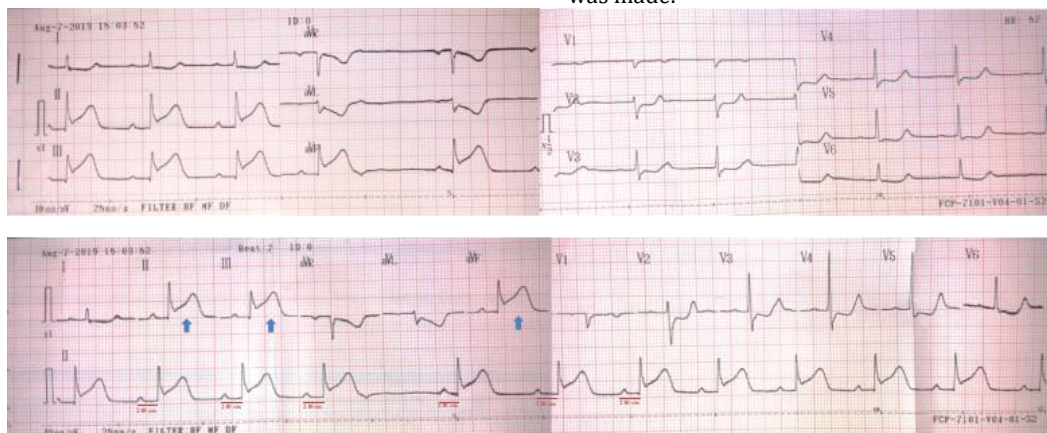
However, this AV conduction disturbance may be transitory. As it may be an ischemic symptom, when revascularization succeed the arrhythmia stops.<sup>6</sup> Although the AV conduction blocks complicating STEMI are frequent, the diagnosis and management remains challenging for every emergency physicians especially in a sub-district hospital. According to our best knowledge, the incidences of first-degree AV block complicating inferior STEMI was not much reported. The purpose of this study was to present a case of resolution from a first-degree AV block complicating inferior STEMI following fibrinolytic therapy in an uncapablecathlab sub-district hospital.

## Case Presentation

A 69-year old male, active smoker (5-10 cigarettes/day) for 45 years, presented to the emergency department (ED) due to syncope 2 hours prior admission. He reported symptoms while farming with sudden onset of diaphoresis, mild dizziness and breathlessness followed by transient loss of consciousness for several minutes. There was no reported seizure activity, and he denied preceding chest pain or palpitations. The patient has no previous history of type 2 diabetes mellitus, hypertension, stroke, and similar symptoms.

In the ED, the patient was alert and asymptomatic. Vital signs included blood pressure was 79/55 mmHg, respiratory rate was 23 per minute, pulse rate was 46 beats per minute, and oxygen saturation was 99% while breathing using oxygen nasal canule 3 L/min. Physical examination, including cardiopulmonary and neurology screen, had normal results.

First emergency physician made the diagnosis of transient loss of consciousness (TLOC) due to vertigo and hypotension. The patient was administered diphenhydramine IV 10 mg/mL. Until second emergency physician to be consulted and ordered electrocardiogram (ECG) also laboratory work-up then definitive diagnosis was made.



**Figure 1.** On admission ECG record showed ST-segment elevation of lead II, III, aVF (blue arrow), and first-degree AV block with constant prolonged PR interval 240 ms

The ECG showed ST-segment elevation in lead II, III, aVF and first-degree AV block with constant prolonged PR interval 240 ms (Figure 1). Laboratory data revealed normal glucose, mild anaemia (Hgb: 10.5 gr/dL, Hct: 28.71%), leukocytosis (12,870/mm<sup>3</sup>), and significant elevation of CK-MB 82.5 U/L (Table 1).

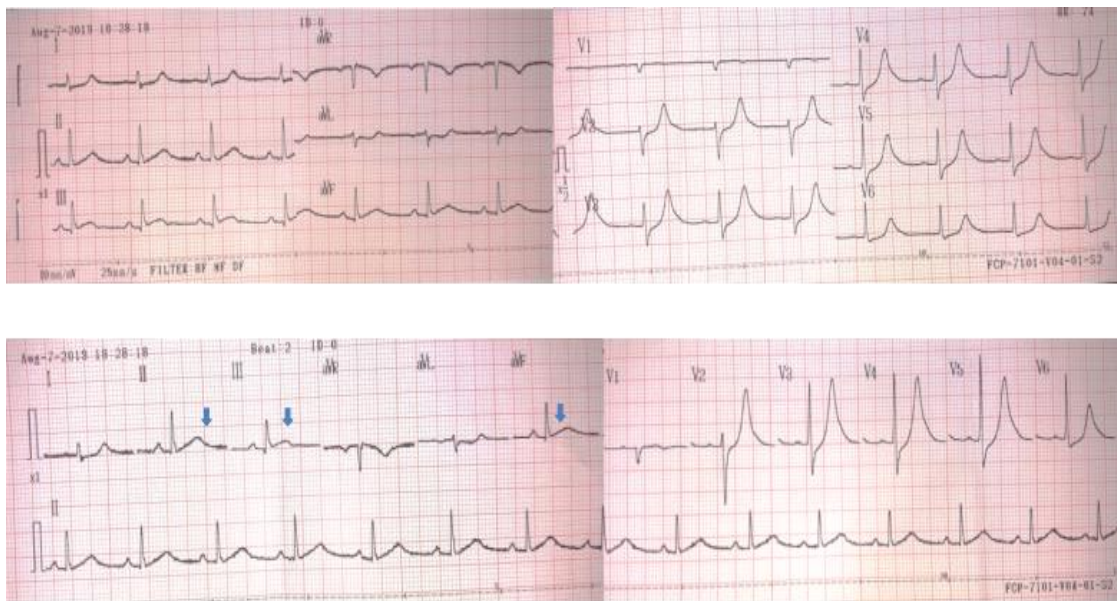
**Table 1.** On-admission laboratory work-up for the patient.

Laboratory Test	Flag	Result	Reference range
Haemoglobin	L	10.5 gr/dL	13.0 – 17.0 gr/dL
Haematocrit	L	28.71 %	40 – 54 %
Leukocyte	H	12,870 / mm <sup>3</sup>	4,000 – 11,000 / mm <sup>3</sup>
Thrombocyte		225,000 / mm <sup>3</sup>	150,000 – 450,000 / mm <sup>3</sup>
Erithrocyte	L	3.54 mil/ $\mu$ L	4.4 – 6.0 mil/ $\mu$ L
Random Plasma Glucose		93 mg/dL	75 – 200 mg/dL
Triglycerides		151 mg/dL	40 – 160 mg/dL
Total Cholesterol		105 mg/dL	150 – 200 mg/dL
LDL-cholesterol		116.4 mg/dL	< 130 mg/dL
Ureum		49.2 mg/dL	10-50 mg/dL
Creatinine	H	1.45 mg/dL	0.6 – 1.4 mg/dL
CK-MB	H	82.5 U/L	< 24 U/L

The patient showed mild hemodynamic instability during his stay at the ED. He was administered 160 mg of aspirin, and 300 mg of clopidogrel. Fluid challenge test was given with rate of 250 mL in 20 min, showed improvement of blood pressure (BP) 93/60 mmHg. Second fluid challenge test was given with a similar rate, showed further improvement of BP 100/75 mmHg. Since primary PCI (pPCI) could not be achieved in  $\leq$  120 min, fibrinolytic strategy was preferred for this patient.

After careful examination of contraindication for fibrinolysis was conducted, the physician decided to administer Streptokinase (1.5 million IU over 60 minutes). During the administration of fibrinolysis therapy with Streptokinase, the patient presented another episode of hypotension and sinus bradycardia (BP: 57/32 mmHg, pulse 37 bpm). The rate of Streptokinase was decreased and Dopamine IV 5 mcg/kg/min was administered.

Post-fibrinolytic ECG was obtained showed signs of successful reperfusion (i) disappearance of breathlessness or chest pain, and (ii) resolution of ST-segment elevation by more than 50% (Figure 2).



**Figure 2.** Second ECG was obtained 30 minutes post-fibrinolytic showed that more than 50% resolution of ST-segment elevation in leads II, III, aVF and also normal PR interval

Clinical risk assessment was conducted at initial presentation using TIMI risk score which revealed 6 and categorized as high-risk patient with 16.1% risk of in-hospital and all-cause mortality at 30 days.<sup>7</sup>

**Table 2.** Clinical risk-assessment using TIMI risk score for STEMI

Parameters	Score
Age 65-74	+2
Diabetes, Hypertension, or Angina	0
Heart rate >100	0
Systolic BP <100 mmHg	+3
Killip Class II-IV	0
Weight <67 kg	+1
Anterior ST Elevation or LBBB	0
Time to treatment > 4 hrs	0
<b>Total Score</b>	<b>6</b>

## Discussion

Although angina is one of the most important symptoms to establish the diagnosis of AMI, in this case syncope is the main symptom that made patient to be admitted to the hospital. Presumably, this is due to a first-degree AV block which complicating inferior wall STEMI in the patient. Emergency physician should raise their awareness about all possibilities that can be the main cause of syncope or transient loss of consciousness, including cardiac arrhythmias during AMI. A study conducted by Rosa et al. (2017) showed that syncope was the main symptom in 13.6% patients with AV block complicating AMI at hospital admission.

AV nodal blocks are common complications in the event of STEMI specifically inferior STEMI. The incidence rate reaches up to 20% exclusively for inferior STEMI. Sinus bradycardia also commonly occurs in inferior STEMI, approximately 40% of the cases in the first 2 hours and decreasing to 20% at the end of the first day hospitalization.<sup>8</sup>

AV nodal conduction blocks which complicating inferior STEMI including 1st, 2nd, and 3rd degree AV block. Most commonly reported was high-degree atrioventricular block (HAVB) complicating Inferior STEMI. However, the etiology of AV block in the setting of inferior STEMI is almost similar.

The AV nodal artery normally receives dual blood supply from the AV nodal artery, which arises from the distal of right coronary artery (RCA) in about 90% of patients or from the distal of left circumflex coronary artery (LCX) in the remainder, and a septal branch of the proximal left anterior descending artery (LAD).<sup>9</sup> The other alternative sources of arterial blood supply to the AV node which have to be taken into account is Kugel anastomotic artery. This artery is a rare variation, but shows an important role as a collateral artery between the proximal LCX or RCA (3%) and for artery that supplies the crux of the heart (distal RCA or distal LCX). It passes anteriorly to the mitral valve annulus, following the lower interatrial septum and may anastomose with the AVN artery.<sup>10</sup>

AVB are very common after the occlusion occurred in inferior STEMI due to obstruction of RCA. Ischemia which occurs during the obstruction of RCA is thought to be sufficient to cause AV blocks in two mechanisms<sup>11</sup>: (i) increased acetylcholine released by the infarcted inferior wall also increased sensitivity of AV nodes to acetylcholine (increased vagal tone resulting from the Bezold-Jarisch cardio-inhibitory reflex/BJR), and (ii) transient damage of the conduction fibers due to lack of blood supply and oxygen.

Other independent risk factors for the AV blocks are advanced age, cardiac insufficiency symptoms, female gender, smoking, hypertension, and diabetes mellitus.<sup>12</sup> A retrospective cohort in Denmark, from 2073 STEMI patients there was documented 67 (3.2%) patients had high-degree AV block (HAVB).<sup>13</sup> Another cohort with 21,807 AMI patients showed an incidence of first-degree,

second-degree and third-degree AVB of 0.8%, 0.8% and 2.5% in the initial presentation consecutively.<sup>4</sup>

According to other previous studies, AV block was more frequent in inferior wall STEMI, in relation to previously described that two pathophysiological mechanisms such as vasovagal reflex (BJR) and transient ischemia theory.<sup>11</sup> However, AV nodal also has two mechanisms of protection against ischemia. First, this is due to AV node receives a collateral blood supply from septal branch of LAD that still can supply during total occlusion of RCA in inferior STEMI. Second, AV node is thought has a high intracellular content of glycogen.<sup>11</sup>

In patients with AMI, to our knowledge, the reversibility of first-degree AV block in the era of fibrinolysis therapy is infrequently described in the literature. The spontaneous resolution of first-degree AV block and ST elevations on 30 minutes after fibrinolysis in the described patient, points to reversible mechanisms. According to our knowledge, the only literature that described a reversibility of AV block during STEMI was conducted by Sasikumar and Kuladhipati<sup>6</sup>. Their report, described a patient who showed spontaneous resolution of complete AV block complicating acute anterior STEMI in the day 5 after received thrombolytic therapy using Streptokinase.<sup>6</sup> In conjunction with previous study, our report suggests that in this case reversible ischemia is prominent pathophysiological mechanism rather than extensive necrosis of the proximal conduction system as the mechanism of first-degree AV block.

TIMI risk score for STEMI was used to measure the risk of in-hospital mortality in this patient and obtained a total score 6 point which equal with 16.1% risk of all-cause mortality at 30 days. TIMI risk score was used to facilitate appropriate decision-making processes and to weigh the risks and benefits of any intervention during hospitalization and post-discharge.

In our case, we reported a case of resolution of inferior ST-segment elevation myocardial infarction complicated with first-degree atrioventricular block after fibrinolytic therapy in incapable sub-district hospital.

## Conclusion

In conclusion, it is important to verify the principal diagnosis and the complications involved in the event of inferior STEMI, like first-degree AVB as well as their proper identification and treatment using combination of the guidelines. Immediate reperfusion therapy is the core management of STEMI patient, either by PCI or fibrinolysis. A successful reperfusion therapy could be seen by traditional criteria of successful reperfusion, and also relieved of the complication associated with STEMI.

## Acknowledgement

We are indebted to all the emergency department crews and treating physicians at Kendal Islamic Hospital, Kendal, Central Java, Indonesia.

*Funding sources*

None

*Competing interests*

None

**References**

1. Rosa SA, Timóteo AT, Ferreira L, Carvalho R, Oliveira M, Cunha P, et al. Complete atrioventricular block in acute coronary syndrome: prevalence, characterisation and implication on outcome. *Eur Hear journal Acute Cardiovasc care*. 2018;7(3):218–23.
2. Singh SM, FitzGerald G, Yan AT, Brieger D, Fox KAA, López-Sendón J, et al. High-grade atrioventricular block in acute coronary syndromes: Insights from the Global Registry of Acute Coronary Events. *Eur Heart J*. 2015;36(16):976–83.
3. Alnsasra H, Ben-Avraham B, Gottlieb S, Ben-avraham M, Kronowski R, Iakobishvili Z, et al. High-grade atrioventricular block in patients with acute myocardial infarction. Insights from a contemporary multi-center survey. *J Electrocardiol [Internet]*. 2018;51(3):386–91. Available from: <https://doi.org/10.1016/j.jelectrocard.2018.03.003>
4. Hreybe H, Saba S. Location of acute myocardial infarction and associated arrhythmias and outcome. *ClinCardiol*. 2009;32(5):274–7.
5. Meine TJ, Al-Khatib SM, Alexander JH, Granger CB, White HD, Kilaru R, et al. Incidence, predictors, and outcomes of high-degree atrioventricular block complicating acute myocardial infarction treated with thrombolytic therapy. *Am Heart J*. 2005;149(4):670–4.
6. Sasikumar N, Kuladhipati I. Spontaneous recovery of complete atrioventricular block complicating acute anterior wall ST elevation myocardial infarction. *Heart Asia*. 2014;4(1):158–63.
7. Silveira DS, Jaeger CP, Hatschbach L, Manenti ERF. Validation of TIMI Risk Score for STEMI. *Int J Cardiovasc Sci*. 2016;29(3):189–97.
8. Musat DL, Cotiga D, Pierce W, Arshad A. Arrhythmias Complicating Acute Myocardial Infarction—BradyarrhythmiasBT - Acute Coronary Syndrome: Multidisciplinary and Pathway-Based Approach. In: Hong MK, Herzog E, editors. London: Springer London; 2008. p. 163–74. Available from: [https://doi.org/10.1007/978-1-84628-869-2\\_16](https://doi.org/10.1007/978-1-84628-869-2_16)
9. Oh IY, Cha MJ, Lee TH, Seo JW, Oh S. Unsolved questions on the anatomy of the ventricular conduction system. *Korean Circ J*. 2018;48(12):1081–96.
10. Saremi F, Torrone M, Yashar N. Cardiac conduction system: delineation of anatomic landmarks with multidetector CT. *Indian Pacing Electrophysiol J*. 2009;9(6):318–33.
11. Cardoso R, Alfonso CE, Coffey JO. Reversibility of High-Grade Atrioventricular Block with Revascularization in Coronary Artery Disease without Infarction: A Literature Review. *Case Reports Cardiol*. 2016;2016:1–6.
12. Kerola T, Eranti A, Aro AL, Haukilahti MA, Holkeri A, Junttila MJ, et al. Risk Factors Associated With Atrioventricular Block. *JAMA Netw open*. 2019;2(5):e194176.
13. Gang UJO, Hvelplund A, Pedersen S, Iversen A, Jons C, Abildstrom SZ, et al. High-degree atrioventricular block complicating ST-segment elevation myocardial infarction in the era of primary percutaneous coronary intervention. *Europace*. 2012;14(11):1639–45.