

# The effect of Jati Belanda (*Guazuma ulmifolia* Lamk) leaves extract on histopathology of rat's kidney

Royhan Rozqie<sup>1\*</sup>, Maulina Diah<sup>2</sup>, Woro Rukmi P<sup>2</sup>

<sup>1</sup>Department of Cardiology and Vascular Medicine, Faculty of Medicine Universitas Gadjah Mada.

<sup>2</sup>Department of Farmacology and Teraphy, Faculty of Medicine Universitas Gadjah Mada

Corresponding author: royhanrozqie@gmail.com

## ABSTRACT

**Introduction:** "Jati Belanda" (*Guazuma ulmifolia* Lamk) is a common tropical plant that its leaves extract has long been used traditionally to treat some tropical diseases and also to reduce body weight as slimming herbs in some of tropical countries. However, the side effect of the administration of "Jati Belanda" leaves extract on the most sensitive excretory organ, the kidney is still not well documented.

**Objectives:** To study the effect of the oral administration of "Jati Belanda" (*Guazuma ulmifolia* Lamk.) leaves extract on the histopathology of the kidney.

**Methods:** The study was a pretest and posttest experimental design using four groups of three rat. The study was a pretest and posttest experimental design using four groups of three rat. The extract of "Jati Belanda" leaves was prepared by boiling of a certain weight of dried "Jati Belanda" leaves in 200 ml of destilated water until the volume of the water became 100 ml. Rat in group I was a control group which were given destilated water, group II were given 0,53 g/100 ml extract, group III were given 1,06 g/100 ml extract and group IV were given 2,12 g/100 ml extract, and the histopathological changes of the rat kidney before, 1 day and 7 days after administration of the extract were compared.

**Results:** Histopathological changes were found in rat kidney following single dose treatment while the control group was not. At one day after administration, mesangial cells proliferation was found in 33,3% of rat in group II and 33,3% of rat in group III, while congestion of blood vessels was found in 66,6% of rat in group III and all rats at the highest dose, group IV. Meanwhile, after 7 days, congestion of micro-vessels was found in all rats of group II, III and IV. Moreover, necrosis of cells was found in 33,3% of rat in group III and infiltration of inflammation cell was found in 66,6% of rat in group IV.

**Conclusion:** A single dose treatment of "Jati Belanda" leaves extract caused histopathological changes on rat kidney. The changes include increased in mesangial cell proliferation, congestion of renal blood vessels in the glomerulus or tubulus, inflamatory cell infiltration and tissue necrosis.

**Keywords:** herbal medicine, "Jati Belanda" *Guazuma ulmifolia* Lamk. Histopathology, kidney.

## INTISARI

**Pendahuluan:** Daun tanaman "Jati Belanda" (*Guazuma ulmifolia* Lamk.) adalah tanaman tropis yang banyak digunakan secara tradisional untuk pengobatan berbagai penyakit tropis dan juga sebagai pelangsing tubuh. Namun demikian efek samping penggunaan daun "Jati Belanda" terhadap organ ginjal yang merupakan organ ekskresi yang sangat sensitive terhadap bahan toksik belum banyak dilaporkan.

**Tujuan:** Untuk mengetahui pengaruh pemberian ekstrak daun "Jati Belanda" (*Guazuma ulmifolia* Lamk.)

terhadap gambaran histopatologi ginjal.

Metode: Penelitian ini menggunakan rancangan pretest posttes eksperimental dengan analisis deskriptif menggunakan 4 kelompok tikus putih (*Rattus norvegicus*). Ekstrak daun "Jati Belanda" disiapkan dengan merebus daun kering seberat dosis dalam 200 ml akuades hingga volume menjadi 100 ml. Kelompok I merupakan kelompok kontrol yang diberi akuades, kelompok II diberi 0,53 g/100 ml ekstrak, kelompok III diberi 1,06 g/100 ml ekstrak dan kelompok IV diberi 2,12 g/100 ml ekstrak. Gambaran histopatologi dari ginjal tikus sebelum, sehari dan 7 hari sesudah pemberian ekstrak dibandingkan.

Hasil: Ditemukan adanya perubahan gambaran histopatologik ginjal tikus sejak satu hari pertama dan pada 7 hari berikutnya pada kelompok perlakuan dibandingkan pada kelompok kontrol yang hanya diberi akuades. Perubahan pada hari pertama berupa proliferasi sel mesangial terjadi pada 33,3% tikus kelompok II dan 33,3% tikus kelompok III dan perubahan kongesti pada 66,6% tikus kelompok III dan semua tikus kelompok IV. Setelah tujuh hari pasca perlakuan, perubahan kongesti meningkat terjadi pada semua kelompok tikus perlakuan dan ditemukan adanya gambaran nekrosis pada 33,3% tikus kelompok III dan gambaran infiltrasi sel radang pada 66,6% tikus kelompok IV.

Simpulan: Pemberian rebusan daun jati belanda dosis sekali pemberian menyebabkan terjadinya perubahan gambaran histopatologis ginjal tikus putih.

Kata Kunci: obat tradisional - *Guazuma ulmifolia* Lamk.- perubahan histopatologik - ginjal

## INTRODUCTION

Indonesia represent one of tropical countries that riched with various species of tropical plants which a numbers of them are beneficial for human health. One of tropical plant that have long been used to promote human health is *Guazuma ulmifolia* Lamk which in Indonesia named as "Jati Belanda". This plant can be easily found in any part of Java and Sumatra Island. In Java "Jati Belanda" also named in javanish called "Jati Londo" and in Suamatra called "Jati Blando". The performace of "Jati Belanda" plant is different with the so called "pohon Jati" or Teak in English or in Latin "Tectona Grandis F.L." in term of the hight and the wide of their leaves. "Jati Belanda" plant is smaller and also their leaves are not as wide as teak leaves (Figure 1). The simillarity is on the tecture of the upper surface of the "Jati Belanda" is not smoth and sinny but corse and a litle bit hairy.

"Jati Belanda" leaves have been used in combination with other plants in most of traditional herbs especialy for reducing cholesterol levels and body weight, with proportion or concentration from 25% to 30%<sup>1</sup>. In Java "Jati



Figure 1. "Jati Belanda" (*Guazuma ulmifolia* Lamk) plant

Belanda" leave also very wellknown used in higher concentration as traditional herb for reducing body weight. Leave and bark of "Jati Belanda" is also known to be used by Indian tribes as anti diarrhoea, dysmenorhae and uteral bleeding<sup>2</sup>. Similarly, Maya tribe used this leaves as suportive treatment during dilivery, to treat digestive disorder, ashma, dysentry,

diarrhea, wound and fever. In Guatemala, "Jati Belanda" plants are used as anti inflammation of the gaster and stomach ache and its leave are used as a tea drink to releaf fever, renal and skin disorder.

The leave of "Jati Belanda" has aolso been known to contain some chemical substances such as alcaloid, flavanoid, sterol, saponine, tannine, glucose, phenolic acid and Calcium oxalate<sup>3</sup>. Sterol has also been known to bind to cholesterol and lipid molecules presence in food and resulted in the decreased of the absorbtion lipid and cholesterol in the intestine, and therefore can be used to lowered cholesterol level in the blood circulation. In other words these can also been used to prevent heart and vascular diseases.

The wide used of "Jati Belanda" in the community since long time as traditional herbs and the absent of monitoring or evaluation of the side effect both instantly or chronically may raise questions of whether these traditional medication has any harmful effect or not especially in relation to the used in high doses or concentration. There are a number of evidence showing the harmful efect of the used of many traditional herbs that containt many chemical compound in high doses or in prolonge time on the function of kidney.

Kidney is internal organ which functions to dialysed approximately 20-30% of total circulated blood in human body. Following filtration by kidney 98-99% of the filtrate will be reabsorbed back and resulted in the increased up to 100-500 times of some toxic material concentration in the tubulus as compared its concentration in the blood circulation. Therefore, renal tubulus become highly risk of the toxic effect of those substances and have high probability to become intoxicated (Ngatidjan, 1991).

The effect of contineous uses of "Jati Belanda" leaves as traditional herbs in the population to the kidney has never been studied yet. The aim of the present study is to evaluate the effect of the consumption of "Jati Belanda" (*Guazuma ulmifolia* Lamk.) infusion on the histological changes of rat kidney.

## MATERIALS AND METHODS

In the current study twenty eight (28) of 2-3 months old male Wistar Rat (*Rattus norwegicus*) weighed around 150-200 gram were used. Approximately 53 gram of "Jati Belanda" leaves were washed with water, and were boild with 200 ml of water until the volume of the water become half of the original (100 ml). After passing the filtrat on to gauss seive and the filtrate was let to settle down in room temperature.

The twenty eight Wistar rats were devided into four groups of 7 rat, the first group was a negative control group which were given 3 ml of distilled water only, the second, third and forth group were given 3 ml of 0.53 gr/100 ml, 1.06 gr/100 ml and 2.12 gr/100 ml of "Jati Belanda" leave extract respectively. One day before intervention one rat from each groups were sacrificized and the kedney were isolated for histipathological examinations. The filtrate were given to each individual rat in all groups using gastric zonde and all rats were placed in cage according to the dosage group. On day 1 and day 7 after intervention 3 rat from each groups were sacrificized and the kidney were isolated for histopathological examination. Histopathological preparation were performed in the Laboratory of Veterinary Medicine Gadjah Mada University. All the slides were stained with Hematoxyline Eosine and examined under the microscope.

## RESULTS AND DISCUSSIONS.

The histipathological examination of the slide were conducted also in the Laboratory of Anatomical Pathology Faculty of Veterinary, Universitas Gadjah Mada and the results shown in Table 1.

Tabel 1. The result of histopathological examination of rat

Time	Intervention	Rat no.1	Rat no.2	Rat no.3
Before intervention	Group I	-		
	Group II	-		
	Group III	-		
	Group IV	-		
1 day after intervention	Group I	-	-	-
	Group II	-	-	MS
	Group III	MS	C	C
	Group IV	C	C	C
7 days after	Group I	-	-	-
	Group II	C	C	C
	Group III	C	C	C,N
	Group IV	C,R	C	C,R

Group I : were given 3 ml of distilled water  
 Group II : were given 3 ml of 0.53 g/100 ml jati belanda extract  
 Group III : were given 3 ml of 1.06 g/100 ml jati belanda extract  
 Group IV : were given 3 ml of 2.12 g/100 ml jati belanda extract  
 C : congestion  
 R : inflamatory cell infiltration  
 N : necrosis  
 MS : Mesangial cell proliferation

As shown in the above table, 4 different histological changes were shown in the haematoxiline eosine staining of the histological preparation of kidney from treated rat. Firstly is congestion (C): enlargement of peripheral blood arteriolar and a picture of interstitials oedema surrounding glomerulus. Secondly, infiltration of inflamatory cells (R), which are characterized by increase number of granulocytes, lymphocytes, monocytes, eosinophiles, netrophiles and basophiles. Thirdly, necrosis (N) which are shown by the closure or collaps of blood vesels and darker tissue appearance as a sign of necrosis of the

kidney tissue. Fourtly mesangial cell proliferation (MS) with appearance of the increase number of mesangial cells compared to normal control. During the experiment, in the treated rats, it is clear that those 4 changes were observed which are reflecting the toxic effect of the “Jati Belanda” in the kidney tissue, even in the 1st day after injection, congestion and mesangial cell proliferation were observed especially in group III and IV which were given higher dose of “Jati Belanda” extract, and also a litle changes such as increase in mesangial cell proliferation had also been observed in 1 of the three rat in group II.

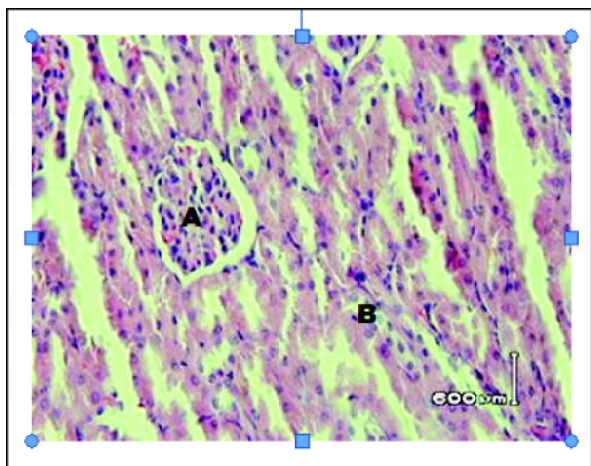


Figure 2. Hystopathological picture of HE stained of rat kidney from group I, one day after administration of 3 ml of aquades (negative control). Magnification 400x (A): normal Glomerulus, (B) normal Tubulus.

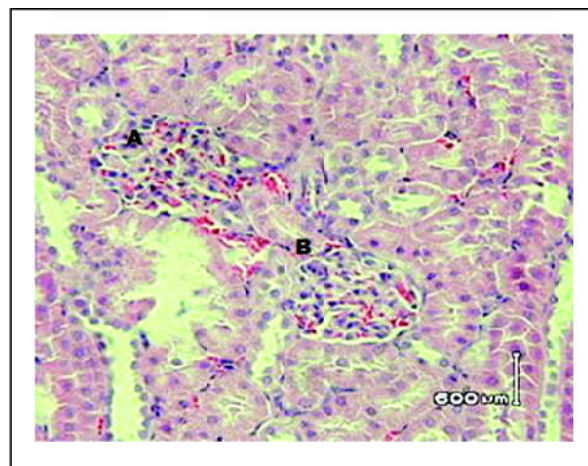


Figure 3. Hystopathological picture of HE stained of kidney preparation from group II at 1 day after administration of 3 ml of 0,53 g/100 ml "Jati Belanda" extract. Magnification 400x. (A): mesangial cell proliferations, (B): slightly congestion of glomerulus.

Examination of the kidney tissue prepared from each group at 1 day before treatment indicated that no one showed pathological changes. Similarly, microscopic examination of hystological preparation of kidney tissue from Rat at one day after treatment in group I which are recieved destilated water shows no pathological changes, no mesangial cell proliferation in the glomerulus, no congestion of blood vessels, no sign of inflamatory processes nor infiltration of any kind of white blood cells and also the absence of necrotic tissue formation. However, pathological changes have been manifested in hystological kidney tissue preparation from rat in group II which are treated with 0.53 g/100 ml extract started at one day after treatment. Microscopic examination of these hystological preparation showed increased proliferation of mesangial cell which fullfilled the overall inter-glomerular spaces. Inspite that changes, a litle number of vascular congestive appearance were also observed in the glomerulus.

Different result showed on the hystological preparation of rat kidney from group III which treated with 1.06 g/100 ml of "Jati Belanda" extract, on one day after treatment started to show hystological changes in a form of congestion of blood vessels in the glomerulus. These congestive appearance are very clearly showed in the hystological preparation of the kidney as scattered of erythrocytic cells fullfilled glomerular spaces and at a lesser degree within inter-tubular spaces of the kidney of treated rats. In one of rat in group III inspite of blood vessel congestion, increased in messangial cell proliferations were also observed. Different hystological appearance were shown in hystological kidney preparation of rat from group IV which recieved 2.12 g/100 ml of "Jati Belanda" extract. Within this group pictures of blood vessel congestion were found predominately in the inter-tubular spaces then in the glomerular part of the kidney sections.

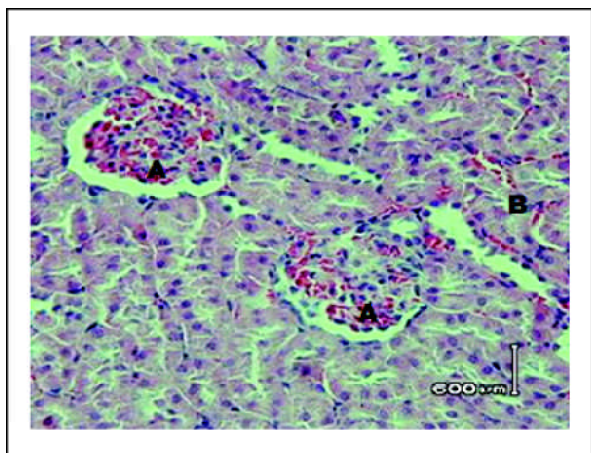


Figure 4. Hystopathological picture of HE stained of rat kidney preparation from group III 1 day after administration of 1,06 g/100 ml of "Jati Belanda" leaf extract. Magnification 400x. (A): sign of congestion in glomerulus, (B): congestion in tubulus.

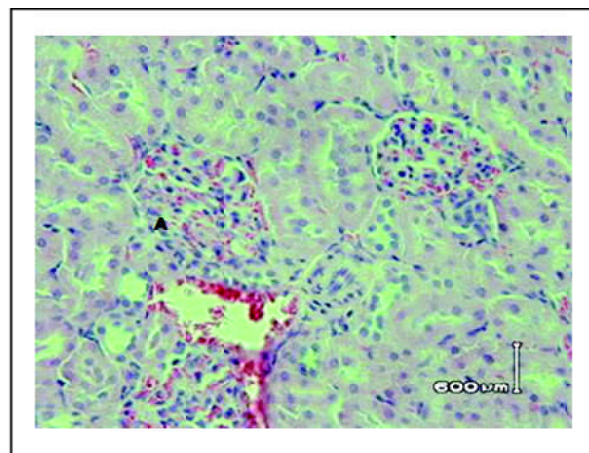


Figure 5. Hystopathological picture of HE stained of rat kidney preparation from group IV at 1 day after administration of 3 ml of "Jati Belanda" extract (2,12 g/100 ml). Magnification 400x. (A): clear picture of vascular congestion.

On day 7 after treatment, hystological preparation were also carried-out upon kidney of all groups of sacrificed rat, stained with

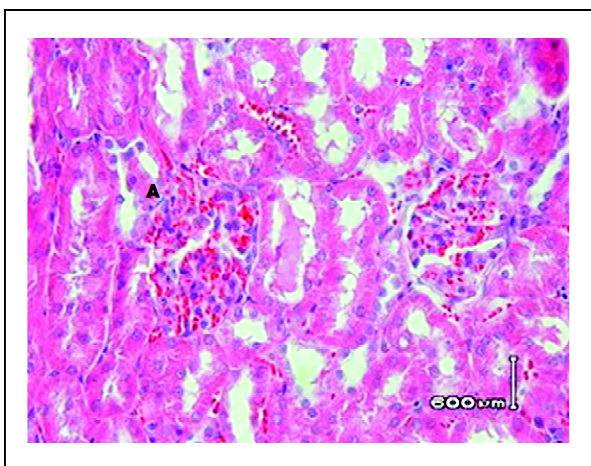


Figure 6. Hystopathological picture of HE stained rat kidney preparation from group II on day 7 after administration of 3 ml (0.53 g/100 ml) of "Jati Belanda" leaf extract. Magnification 400x. (A): picture of vascular congestion in glomerulus

hematoxylline and examined microscopically. Within group I, microscopic pictures still showed normal conditions within glomerular as well as within tubular part of the rat kidney. Congestion of blood vessels, increased of mesangial cell proliferation, infiltration of inflammatory cells and necrotic tissue formation are absent within kidney tissue preparation from rat from group I. Meanwhile in group II which recieved 0.53 g/100 ml of "Jati Belanda" extract, the hystopathological preparation of the rat kidney shows picture of more severe congestion with more abundance of erythrocytic scattered as compared to the previous (day 1) hystopathological pictures of the same group.

Clearer pathological picture were shown in hystopathological preparation of rat kidney from group III which received higher doses (1.06 g/100 ml) extract of "Jati Belanda". Those pathological changes look more prominent such as the sign of blood vessel congestions accompanied by necrotic tubular cells appearance in some areas of the slide field. The most severe pathological cahnges were shown in the kidney preparation of rat from group IV which recieved 2.12 g/100 ml of "Jati

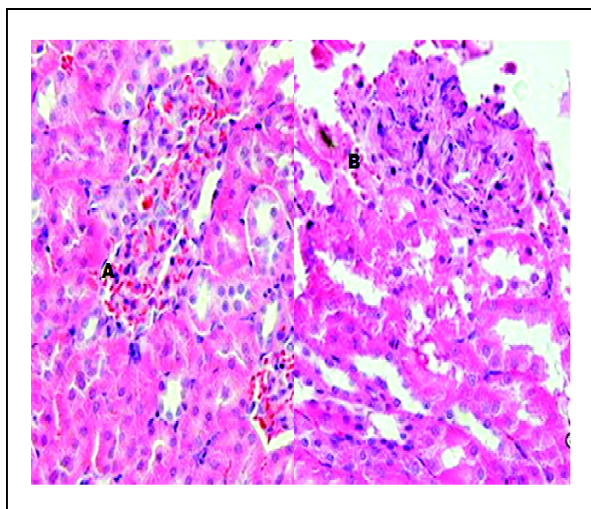


Figure 7. Hystopathological picture of HE satinned rat kidney preparation from group III on day 7 after administration of 3 ml (1.06 g/100 ml ) of “Jati Belanda” leaf extract. Magnification 400x. (A): picture of vascular congestion in glomerulus, (B): tissue necrosis in tubulus.

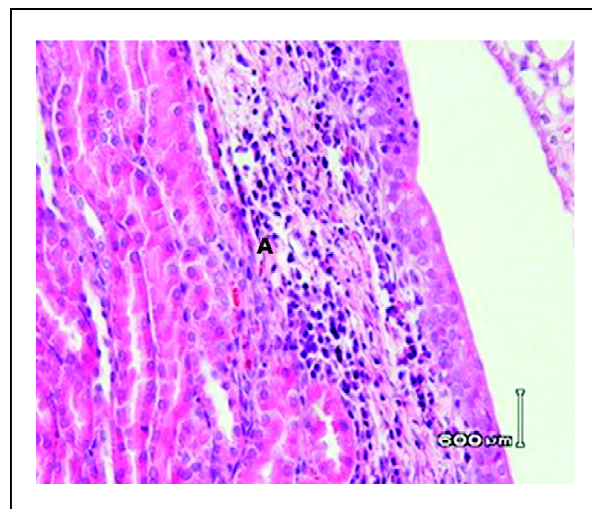


Figure 8. Hystopathological picture of HE satinned rat kidney preparation from group IV on day 7 after administration of 3 ml (2.12 g/100 ml ) of “Jati Belanda” leaf extract. Magnification 400x. (A): picture inflammatory cell infiltration.

Belanda” extract. The pathological changes include extensive expansion of inflammatory cells infiltration which reach both cortex as well as medular parts of the kidney, accompanied by extensive blood vessel congestion through-out the glomerular part of the rat kidney.

Taylor and Leslie<sup>2</sup> reported that the leaf of “Jati Belanda” contains several identified chemical compounds which included in alcaloides group such as caffeine, beta-Caryophyllene (Sesquiterpene), Farnesoles cis-2-trans-8 (Sesquiterpene), Ent-Kaur-16-en-19-oic acid (Diterpene), and Precocene I (oxygen heterocycle). “Jati Belanda” leafes also known to contain several biochemical compound including alcaloides, flavanoides, Saponin, Tannin, mucous compound, glucose, Turpentic acid (Damar), Crystal of Calcium oxalate<sup>3</sup>. Coffeine may cause dilatation of blood vessels, including coronary and pulmonaly blood vessels due to direct effect on the myofibriles of the muscular layer within the blood vessels<sup>4</sup>.

Ambrosio *et al.*<sup>5</sup>, identified that *kaurenoic acid* or Ent-Kaur-16-en-19-oic acid are included in Carboxilate groups which may act as anti-spasmodic vasorelaxantia. berperan dalam grup karbosiklik sebagai antispasmodik dan vasorelaksan. One of the flavanoides compound namedly Pro-antocyanidine will produce Antocyanidine by boiling the “Jati Belanda” leaf in 2 Molar of HCL for 30 minutes<sup>6</sup>. In relation with this finding, Caballero-George C. *et. al.*<sup>7</sup> also reported that Proanthocyanidin may effect on the inhibition of the attachment of Angiotensin II on to the Angiotensin II type 1 (AT1) receptors.

Angiotensin II (also called Hypertensin or Angiotonin) may cause contraction of the small arterioles and resulted in the increased of systolic as well as diastolic blood pressure. These compounds represent one of the strongest vasoconstrictors compound, which in normal person shows vasoconstrictor activities of 4-8 times as compared to Nor-epinephrines<sup>8</sup>. Another reseacher also showed that stimulation of mesangial cells in the kidney with Angiotensine

may resulted in contraction of mesangial cells and resulted in the decreased of blood flow into the glomerular capillaries of the kidney<sup>9</sup>. Therefore, supression of the angiotensine hormone will resulted in the suppression of mesangial cell contraction. Mesangial cells represent cellular component that support the capillary exisstance within the glomerulus, and these cells are also shows phagocytic activities and usually will prolifetares in certain kidney diseases<sup>9</sup>.

Tanine may be absorbed through the the damaged or wounded skin and through mucous membrane. Tannine will be digraded into gallic acid form and glucose in the intestine. Gallic acid is not astringent compound and mostly will be absorbed in the intestine, and the presence of gallic acid in the kiney arterioles may produce renal damage<sup>10</sup>.

Saponine is a substance that known to cause haemolysis of the red blood cells and produce irritation of the gastro-intestinal tract<sup>10</sup>. Therefore it is also possible that these substance also may contributes to the damage of the kidney of the experimental group of the rat.

Ent-Kaur-16-en-19-oic acid is a biochemical substance that may act as vaso-relaxant. However, these substance also sometimes used to treat patient infected with Trypanosome parasites<sup>11</sup>. Ent-Kaur-16-en-19-oic acid also shows to have some interesting activities including as anti-microbes, cytotoxic agent, anti-inflammatory and anti-protozoa<sup>11</sup>. The strong cytotoxic effect of these ent-Kaur-16-en-19-oic acid may responsible for the necrotic pictures shown in tubular cells of the kidney of experimental rat in these study.

Precocene I compound that found in "Jati Belanda" leaf probably also have an insecticidal action due to its cytotoxic activities. Farazmand and Chaika<sup>12</sup>, reported that precocene may cause suppression on the action of juvenile hormon, and also have a strong cytotoxic against certain arthropodes or insect which act to cause necrosis of the parenchymal glandular cell that produce Juvenile hormon.

## CONCLUSION

Studies on the effect of "Jati Belanda" leaf extract have been conducted on groups of rat in the laboratory and the result indicated that:

1. Oral administration of "Jati Belanda" leaf extract with dose of 0.53 g/100 ml, 1.06 g/100 ml, and 2.12 g/100 ml produced microscopic hystopathological changes on the haematoxyline stained rat kidney preparation.
2. Hystopathological changes that been observed in the treated rat groups include increased in mesangial cell proliferation, congestion of renal blood vessels, inflamatory cell infiltration and tissue necrosis.

## ACKNOWLEDGEMENT

We thanks to the Dean of the Faculty of Medicine Gadjah Mada University for the opportunity and making the grant available to conduct this study. Thanks also to the all staf and Head Department of Anatomical Pathology Faculty of Veterinary Medicine, Gadjah Mada University for all helps and assistance.

## REFERENCES

1. De Padua LS, Bunyaprapatsara N & Lemmens RHMS. Plant Resources of South East Asia 12(1) dalam Medicinal and Posionous Plants. *Proasca* Indonesia-Bogor, 1999;36-48:286-8.
2. Taylor and Leslie. *The Healing of Rainforest Herbs*, 2005. URL: <http://www.rain-tree.com>
3. Syamsuhidayat SS & Hutapea J. *Inventaris Tanaman Obat Indonesia I*. Jilid I. Departemen Kesehatan Republik Indonesia. Badan Penelitian dan Pengembangan Kesehatan. Jakarta, 1991;274-5.
4. Sunaryo. Perangsang Susunan Saraf Pusat, dalam: Ganiswarna, S.G. *Farmakologi dan Terapi*. Edisi 4. Bagian Farmakologi Fakultas Kedokteran UI. Jakarta, 1995;226-8.
5. Sergio Ambrosio R, Carlos Tirapelli R, , Silvia T Coutinho, Dionéia de Oliveira CR, Ana de Oliveira M, Da Costa Fernando B. *Role of the carboxylic group in the antispasmodic and vasorelaxant action displayed by kaurenoic acid*. Pharmaceutical Press, 2004.



6. Harborne JB. *Metode Fitokimia: Penuntun Cara Modern Menganalisis Tumbuhan*. Eds 2. Penerbit ITB. Bandung, 1987;69-72, 102-4.
7. Caballero-George C, Vanderheyden PM, De Bruyne T, Shahat AA, Van den Heuvel H, Solis PN, Gupta MP, Claeys M, Pieters L, Vauquelin G, Vlietinck AJ. *In vitro inhibition of [3H]-angiotensin II binding on the human AT1 receptor by proanthocyanidins from Guazuma ulmifolia bark*. Departement of Pharmaceutical Sciences, University of Antwerp. Antwerp. Belgia. Sciences, University of Antwerp. Antwerp. Belgia, 2002.
8. Ganong WF. *Fisiologi Kedokteran*. Edisi 17, cetakan II. Penerbit Buku Kedokteran EGC. Jakarta. 1999;447.
9. Leeson C Roland, Leeson Thomas S.& Paparo, Anthony A. *Buku Ajar Histologi (Textbook of histology)*. Penerbit Buku Kedokteran EGC. Jakarta, 1996;427-49.
10. Reynolds JEF & Prasad Anne B. *Martindale The Extra Pharmacopoeia*. Twenty-eight Edition. The Pharmaceutical Press. London, 1982;287:376.
11. Vieira Henriete S, Takahashi, Jacqueline A, de Oliveira Aláide B, Chiari, Egler and Boaventura, Maria Amélia D. Novel Derivatives of Kaurenoic Acid: Preparation and Evaluation of their Trypanocidal Activity. *Journal of the Brazilian Chemical Society* vol.13 no.2. São Paulo, 2002.
12. Farazmand H & Chaika S Yu. *Effect of Precocene<sup>2</sup> - Juvenile Hormone Inhibitor on Chemoreceptor Organs of Colorado Potato Beetle Larvae, Leptinotarsa Decemlineata Say. (COLEOPTERA: CHRYSOMELIDAE)*. Iranian Researchers Conference in Europe. Leeds, UK, 2005.