



Journal Homepage:
<https://jurnal.ugm.ac.id/rpcpe>

RPCPE

ISSN 2613-943X (print)
 ISSN 2620-5572 (online)

Review of Primary Care Practice and Education
 (Kajian Praktik dan Pendidikan Layanan Primer)

Scabies in an Adolescent with Poor Personal Hygiene

Dian Isti Angraini¹, Neema Putri Prameswari², Eko Budi Susanto³

¹ Department of Public Health and Community Medicine; Faculty of Medicine; Universitas Lampung; Indonesia

² Faculty of Medicine; Universitas Lampung; Indonesia

³ Kedaton Public Health Center; Bandar Lampung; Indonesia

Corresponding Author:

Dian Isti Angraini: Department of Public Health and Community Medicine; Faculty of Medicine; University of Lampung; Jl. Soemantri Brojonegoro No. 1, Kedaton, Lampung - 35145, Indonesia

Email: riditie@gmail.com

To cite this article:

Angraini DI, Prameswari NP, Susanto EB. Scabies in an adolescent with poor personal hygiene. Rev Prim Care Prac and Educ. 2022; 5(2): 78-83.

INTRODUCTION

Skin disease is one of the public health problems in developing countries such as Indonesia. One of the common skin diseases is scabies, a parasitic infestation that is highly contagious and can cause significant morbidity. Scabies can cause prolonged itching and excoriation, resulting in secondary infection¹.

Scabies is a skin disease caused by infestation and sensitization of the parasite, *Sarcoptes scabiei var. hominis*. Scabies is transmitted through several ways, namely direct contact with the skin or indirectly through clothing, bed linen, mattresses, and toiletries. Symptoms that appear are itching and skin eruptions in the form of papules, nodules, and vesicles due to a hypersensitivity reaction². People who are infected with scabies can transmit it to others even though they do not show symptoms until the infection is successfully treated and the mites and eggs are destroyed³.

According to the World Health Organization (WHO), scabies is one of the most common skin disorders in developing countries and is estimated to occur in 200 million people. The prevalence is estimated to range from 0.2% to 71%, and the prevalence in children reaches 5-10%. Scabies often affects young and old people in a community. The highest cases occur in tropical countries, low economic communities, and densely populated settlements. The problems that often occur are reinfestation and secondary infection. In 2017, scabies was categorized as a Neglected Tropical Disease (NTD) by the WHO⁴.

According to data from the Ministry of Health of the Republic of Indonesia, the prevalence of skin diseases throughout Indonesia in 2012 was 8.46%. This increased in 2013 to 9% making scabies ranked third out of 12 skin diseases that often occur⁵. In Indonesia, scabies is a skin disease that continues to be a public health problem⁶.

Research conducted by Wibianto and Santoso stated that the number of scabies cases at the Ciwidey Health Center in West Java in the 2015-2020 period was 1,725 cases with the highest prevalence in the age group 0-16 years⁷. In Lampung Province, in 2014 there were 7,960 people, which experienced a significant increase from 2012 which amounted to 2,941⁸. At the Kedaton Public Health Center, Bandar Lampung, in 2020 there were 130 new cases and 45 old cases of scabies.

The widespread transmission of scabies is caused by several factors, including low socio-economic level, low knowledge about scabies disease and poor hygiene⁹. In addition, other factors such as room occupancy density are also found to influence the incidence of scabies¹⁰. Low knowledge about scabies and poor personal hygiene can reduce motivation and participation in the prevention and eradication of scabies in the community. Improper or delayed therapy affects the patient's quality of life and increases transmission. If left untreated, scabies can affect the family's quality of life due to sleep difficulties, absenteeism from school, and social isolation, especially in children¹¹.

Primary health services have a very important role in scabies disease, especially in terms of preventing the disease to the community, establishing a diagnosis, appropriate therapy, total eradication, and prevention of recurrence. Therefore, a holistic diagnosis and appropriate comprehensive management of any scabies case using a family medicine approach is needed¹². The importance of eradication in the management of scabies cases is also very necessary to break the chain of disease transmission to the community.

RESEARCH METHODS

This case report used data obtained from primary and secondary sources. Primary data were obtained through

history taking (autoanamnesis and alloanamnesis with patient’s family members), physical examination, and home visits, to complete the family, psychosocial and environmental data. Secondary data were obtained from the patient’s medical records. Assessment was based on a holistic diagnosis from the beginning, process, and end of the study qualitatively and quantitatively.

RESULTS

Case Report

The patient, a 15 years old boy came to the Kedaton Public Health Center with complaints of red nodules accompanied by itching between his fingers and toes, stomach, back, and groin since two months ago. Complaints were accompanied by itching that worsened at night. The patient liked to scratch the nodules with his long finger nails until they broke open and caused sores. The previous complaint had been treated with betamethasone ointment and antiseptic solution for one week but his condition did not improve. The patient was worried that the itching will get worse and not go away. Also, it made the patient unable to sleep.

The patient hoped that the red nodules with itching would disappear, and the disease can be cured soon so that the patient can carry out activities as usual. The patient thought his complaint happened because he has a food allergy from eating eggs and fish. Similar complaints were experienced by the patient’s mother who was at home and also, among some of his playmates. He denied a history of similar complaints, any history of eczema, asthma, and there was no history of drug and food allergies, nor any history of insect bites.

Biological and Psychosocial Diagnoses

A holistic diagnosis was formulated since the patient was having a complaint of red nodules accompanied by itching between the fingers and toes, stomach, back, and groin

Assessment

Table 1. Family SCREEM Analysis

Source	Pathology	Note
Social	Good interaction between family members, patient participation in active community activities. Currently, the patient spends time at home with family members.	-
Culture	Satisfaction or pride in a good culture can be seen from daily interactions both in the family and in the environment, and many cultural traditions are still followed, including using Javanese language, manners, and politeness.	+
Religious	The application of the teachings is also good; this can be seen from the sufferer and their family who routinely prays five times a day; the patient’s mother also wears headscarves and the patient’s father often prays at the mosque.	-
Economic	This family is classified as middle class; primary needs can be met; secondary needs and economic plans are adequate; a priority scale is needed to meet the needs of life	+
Educational	Low education of family members, patient, and parents are elementary school graduates	+
Medical	In seeking health services, families use Puskesmas services and use the Jamkesmas card (BPJS) for treatment. Patient claims that they will only seek treatment if there are complaints, and patient rarely does health checks regarding his illness.	+

since two months ago as described above. The patient is considered as an adolescent, with poor personal hygiene and a lack of health knowledge.

The diagnosis was made based on the patient’s history, physical and lab examinations, which were conducted both at the Community Health Center (*Puskesmas*) and during home visits. Generalist status examination was normal. The results of local examination / dermatological status showed that in the bilateral manus, bilateral antebrachial, bilateral axilla, posterior thorax, umbilical, bilateral inguinal, and bilateral pedis regions there were skin-colored papules, some erythematous, multiple, well-defined, billion to lenticular in size, and scattered discretely. Some are confluent, some are accompanied by thin blackish-brown crusts, erosion, and excoriations.

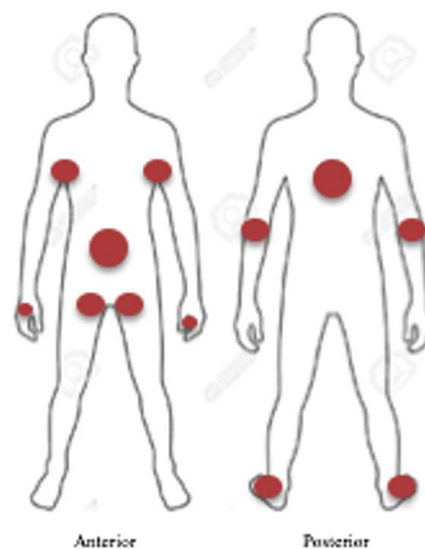
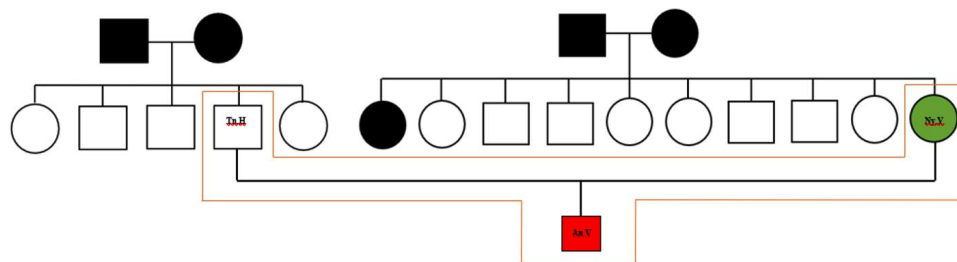


Figure 1. Regions with skin disorders.

Table 2. Family APGAR Analysis

Source	Component	Score
Adaptation	Adaptation is the utilization of intra and extrafamilial resources for problem-solving when family equilibrium is stressed during a crisis.	2
Partnership	The partnership is the sharing of decision-making and nurturing responsibilities by family members.	2
Growth	Growth is the physical and emotional maturation and self-fulfillment that is achieved by family members through mutual support and guidance.	0
Affection	Affection is the caring or loving relationship that exists among family members.	1
Resolve	Resolve is the commitment to devote time to other members of the family for physical and emotional nurturing. It also usually involves a decision to share wealth and space.	2
Total		7 (Good family function)



Information:

- Man, died
- Woman, died
- Man, live
- Woman, live
- Have similar complaint
- ▭ Stay at home

Figure 2. Genogram of the patient

Formulation of the problem

This patient’s holistic diagnosis was formed from five aspects, namely personal aspects, clinical aspects, internal risk aspects, external/psychosocial/environmental risk aspects, and functional degree aspects. The personal aspects consisted of the reasons for coming, namely the appearance of red nodules accompanied by itching, especially at night which were getting worse between the fingers and toes, stomach, back, and groin since two months ago; worries in the form of complaints of itching getting worse and not disappearing and making the patient unable to sleep, hope that the redness of the rash accompanied by itching will disappear, and the disease can be cured soon so that the patient can carry out activities as usual; and the perception that complaints arise because he has food allergies in the form of eggs and fish.

The clinical aspect of this patient was scabies (ICD 10:B86, ICPC-2:S72). Internal risk aspects include the patient often staying at a friend’s house who has similar complaints and exchanging clothes, poor personal hygiene, the patient

occasionally taking a bath once a day, rarely cutting nails, likes to scratch skin lesions, rarely hanging out mattresses and pillows, rarely washes bed linen, pillowcases, and towels, lack of patient knowledge about the disease, risk factors, treatment, and the risk of transmission, inappropriate treatment behavior, patient seeking treatment to a pharmacist, and patterns of curative treatment.

External/psychosocial/environmental risk aspects include the presence of similar complaints in the social environment, namely playmates who often stay and sleep on the same bed so that transmission is possible, the presence of similar complaints in the family, namely the mother, so that if the patient and mother do not take concurrent treatment efforts, the chain of transmission will not be broken, the family’s knowledge is lacking about the patient’s illness, treatment methods and prevention and termination of the chain of transmission to assist the healing process of the disease, such as washing clothes, bed linen, towels with hot water and drying mattresses, sheets, clothes, towels under the scorching sun, and inappropriate family medication behavior and treatment patterns are curative. The functional

degree aspect is 1 (one), namely the patient can carry out daily activities such as the state before the illness.

Management

The interventions given to this patient are education and counseling to patient and families about aspects that must be modified and must be known to prevent the possibility of complications and recurring complaints. The interventions that will be done are divided into patient-centered, family-focused, and community-oriented. In the patient-centered intervention, pharmacological and non-pharmacological therapies were given. Pharmacological therapy was done by treating the disease by giving 2-4 ointments (containing 2% salicylic acid and 4% sulfur precipitated), the ointment is applied once a day after bathing for 8-10 hours for 3 consecutive days; and providing anti-histamines, namely chlorpheniramine maleate (CTM) tablets 3x4 mg to reduce itching which is quite annoying, especially at night.

Non-pharmacological therapy by providing education about scabies disease including causes, risk factors, transmission, treatment, efforts to help cure the disease, termination of transmission, and complications of the disease if not treated; handling infectious linen, including washing bed linen, pillowcases, and towels more often (1-2 weeks) in the right way by soaking in hot water and drying in the sun; drying mattresses and pillows in the sun; avoid sharing personal items (clothing and toiletries) with other family members; changing clothes after every bath or after sweating excessively, separating the washing of the patient's clothes from other families, and cutting off transmission by avoiding direct or indirect contact with friends or other people in the home and social environment who have the same complaint to avoid repeated infections.

Family-focused interventions are done by providing information and education regarding scabies disease including causes, signs and symptoms, transmission, and management; the importance of personal hygiene and the environment around the house; disease eradication, namely regarding the habits and procedures for transmission of scabies; and complete eradication of family members to immediately seek medical attention or use the same treatment as the patient if similar clinical symptoms appear.

Community-oriented interventions are done by providing education and information on how to transmit and prevent scabies disease which can be transmitted to other family members, playmates, or neighbors, for example by separating personal clothes, towels, bed linen, both in the washing process and in use and not to touch each other. It is important to direct, and complete eradication and also explain to playmates or neighbors to immediately go to the nearest health care facility if similar clinical symptoms appear.

DISCUSSION

The case study was conducted on a patient 15-year-old boy who presented on June 29, 2021, to the Kedaton Public Health Center with a complaint of redness and itching since two months ago and was diagnosed with scabies. Initially,

this complaint was felt in the groin and between the fingers, then spread to the armpits, abdomen, and back. The patient tried to treat the disease with Betamethasone ointment but the symptoms have not improved.

The patient is a private junior high school student in Bandar Lampung who is on vacation. The patient has a playmate with similar complaints. Because he was on vacation, the patient admitted that he often exchanged clothes and slept in the same bed with his friend. Currently, the patient's mother claimed to have complaints of similar itching on the skin since one week ago. Scabies can cause uncomfortable itching, especially at night. If left unchecked, the itching can interfere with sleep and even daily activities. In addition, scabies is a skin disease that is easily transmitted either through direct or indirect contact. So, in this case, other family members have a high potential to be infected. Therefore, it is necessary to guide families so that family members can participate in preventing transmission and treating disease.

Scabies is a skin disease caused by infestation and sensitization to *Sarcoptes scabiei* var. *hominis* and its products. This disease is highly contagious and is characterized by itching at night, affecting groups of people, with a predilection for the folds of skin that are thin, warm, and moist. Transmission occurs through the transfer of adult mites from one infected individual to another by direct skin-to-skin contact and indirectly through contaminated clothing, towels, bed linen, or other items. The predilection areas for this disease are in places with a thin stratum corneum, namely between the fingers, the volar part of the wrist, the outer elbow, the axillary folds, areola mammae, umbilicus, buttocks, external genitalia, and lower abdomen.

The diagnosis of scabies cases is based on the finding of two of the four cardinal signs, namely nocturnal pruritus, attacks in groups, the discovery of tunnels (cuniculus) in the form of straight lines or windings of white or gray color with papules or vesicles tip, and the parasite *Sarcoptes scabiei*. In this patient, two cardinal signs of scabies were found, namely nocturnal pruritus and attacks in groups, while the other two cardinal signs could not be found because further microscopic examination was needed, but this examination was not done because the unavailability of facilities and infrastructure at the public health center.

On physical examination, the general condition appeared to be mildly ill, compos mentis consciousness, with weight 45 kg, and height 155 cm. Measurement of nutritional status using the body mass index indicator per age for boys aged 15 years with the Center for Disease Control (CDC) growth chart indicated the results are between the 25th percentile and 50th percentile, with the impression of normal nutritional status.

On examination of the dermatological status, it was found in the bilateral manus, bilateral antebrachial, bilateral axillae, posterior thorax, umbilical, bilateral inguinal, and bilateral pedis there were skin-colored papules, some erythematous, multiple, well-defined, billion to lenticular in size, scattered

discretely, some confluent, some accompanied by thin blackish-brown crusts, erosions, and excoriations. This is by the theory which states that scabies has a predilection for the occurrence of scabies in areas with thin skin folds, such as between the fingers, the volar part of the wrist, the outer elbow, the axillary folds, areola mammae, umbilicus, buttocks, external genitalia, and lower abdomen. The lesions seen in the patient are also by the theory which states that in scabies, papules, vesicles, etc. can be found, erosions, excoriations, crusts and secondary infection due to scratching can also be found. The typical skin lesions found in this case of scabies can be canaliculi or tunnels, papules, vesicles, and pustules at the site of predilection¹¹.

The first meeting was held when the patient came to the Kedaton Public Health Center on June 29, 2021, to seek treatment. At this first meeting, a holistic history and physical examination were done, and then informed consent was given to the patient to ask for approval to carry out family development along with its aims and objectives. The patient and family agreed verbally, then communication was continued via telephone and WhatsApp media. During the first visit, July 2, 2021, a holistic history was taken including identifying the family map, biological, psychosocial, economic functions, health behavior, health facilities and infrastructure, and the home environment. From the results of the history and this visit, a list of problems that exist in the patient and family can be obtained so that the type of intervention that will be given can then be planned, so that on the second visit an intervention according to poster and PowerPoint media can be done.

At the Public Health Center, the patient was given therapy in the form of 2-4 ointments and 4 mg CTM antihistamine. This is by the specific management of scabies patients, namely using drugs to kill scabies mites and using antihistamines to reduce itching symptoms. Precipitated sulfur (sulfur precipitate), with levels of 3-6% available in the form of ointments, 5-40% petrolatum can be used within 8-15 hours for 3 consecutive days. It does not irritate, and can be used on babies less than two years old, pregnant women, and breastfeeding mothers¹³.

EDUCATION

The management of this patient was done with a family medicine approach through coaching and education interventions. This activity was conducted four times which included the first meeting in person at the public health center, then communicating via telephone and WhatsApp media. The second meeting was held at the patient's home while still applying the appropriate health protocol. In addition, communication was done via video conference for the third and fourth meetings, because the patient and family were out of town and the patient's mother had a fever. This is done to minimize contact considering that we are still in the COVID-19 pandemic situation.

In the family map, social functions, infrastructure, and home environment there were no problems related to the patient's condition. In the aspect of human biology, there were problems in the form of complaints of red nodules

accompanied by itching between the fingers and toes, stomach, armpits, back, and groin. This complaint was felt since two months ago. The patient tried to treat it with betamethasone ointment but the complaints have not gone away. The patient does not know what type of disease he is suffering from and what factors have caused the treatment to be unsuccessful so far. The patient thought his complaint was caused by an allergy to eggs and fish. This problem underlies the intervention that will be done which includes providing education for knowledge about scabies disease, transmission, risk factors, and proper treatment as well as the importance of personal and environmental hygiene.

One visit to the patient's home was done to fulfill a holistic history and see the condition of the house to determine whether there was an influence of the condition of the home environment on the patient's illness and identify problems experienced by the patient and his family. The second visit should be done to intervene according to the problems that have been identified, but because the patient and family are in North Lampung, and the patient's mother is experiencing a fever, the second visit was made online via video conference to intervene in the problem. The intervention was done using media in the form of posters and Powerpoints containing the causes of scabies, risk factors, transmission, efforts to be made, and personal hygiene to help the patient's healing process. Management was given to the patient and family members in the form of medical and non-medical with a patient-centered, family-focused, and community-oriented approach.

Medical management was given to patients in the form of 2-4 ointments (containing 2% salicylic acid and 4% sulfur precipitated) and antihistamine CTM 3x4 mg. Patient-centered non-medical management includes education about scabies disease including causes, risk factors, transmission, efforts that must be made to help cure the disease, as well as ways to prevent, educate patients to maintain personal and environmental hygiene. In addition, education is also given on how to handle infectious linen to break the chain of transmission and avoid direct or indirect contact with friends or other people in the home environment who have the same complaint to avoid repeated infections. Education is also done for patients to seek treatment at the public health center or other health services if their complaints do not improve. In family-focused approach, education is done about the patient's scabies disease to his family, and it is also explained to the family to immediately check themselves or use the same treatment as the patient if clinical symptoms appear. Education is also done to improve the patient's condition and their adherence to appropriate treatment behavior.

SOCIAL SUPPORT

As previously discussed, scabies is a disease that attacks in groups, especially people who live together or in the same environment. Thus, it is important to carry out treatment with a community-oriented approach which includes providing education about scabies to residents, especially to some of the patient's friends who have similar complaints, how to maintain personal and environmental hygiene, as

well as encouraging people who have similar complaints to immediately seek treatment, to the nearest health service as an effort to break the chain of transmission of scabies. Due to limitations due to the pandemic and obstacles in gathering with communities around the patient's residence, coaching activities can be done through patients to people around by providing educational media in the form of posters and calendars.

PERSONAL HYGIENE

The evaluation was done seven days after the intervention was carried out via WhatsApp, considering the limitations due to the COVID-19 pandemic. Evaluation activities aim to assess whether the expected targets of intervention activities are achieved. A re-analysis was conducted on the patient after approximately three weeks of treatment and the results showed that the patient's itching complaints had greatly reduced and he was not disturbed when sleeping. The patient has reduced the habit of scratching the lesions, but occasionally it is still done because of itching. However, the skin lesions scars which were still found and some nodules began to disappear slowly. In addition, the patient also no longer stays and exchanges clothes with friends who have similar complaints. The patient has improved personal hygiene by bathing twice a day, although not every day. The patient has also followed the advice to trim his nails. In addition, interviews were conducted with the patient's mother and it was found that the his mother had washed all of their clothes, towels, bed linen, and blankets using hot water and detergent, and dried them in the sun. The patient's mother who had similar complaints had also gone to the doctor and received the appropriate treatment.

The patient used the ointment according to the recommendation, which is used all over the body and left for 8-10 hours, then takes a shower in the morning. The drug is used for three consecutive days. Treatment was repeated once after one week. The effectiveness of sulfur ointment in the treatment of scabies was seen to result in improvement within three weeks of treatment even though scabies lesions were still visible. Scabies lesions will disappear completely after one month of treatment¹⁴.

After the intervention and evaluation, there was a change in knowledge that was much better for the patients and their families regarding scabies disease, after the education on transmission methods, personal and environmental hygiene had been conducted.

HANDLING INFECTIOUS LINEN

Eradication needs to be done to break the chain of transmission (handling infectious linen), which includes washing bed linen, pillowcases, and towels washed in the right way (soaked in hot water and washed thoroughly) as recommended, with the mattresses, and pillows dried in the sun. The patients and families no longer use towels, clothes, or other personal items at the same time, while the towels are always dried in the open air after use, pillowcases bolsters and bed linen are also changed every two weeks.

CONCLUSIONS

The holistic management of scabies patients with a family medicine approach, in this case, has succeeded in helping the healing process of the patient's disease and preventing transmission in the community.

REFERENCES

1. Mitchell E, Bell S, Thean LJ, Sahukhan A, Kama M, Koroivueta A, et al. Community perspectives on scabies, impetigo and mass drug administration in Fiji: a qualitative study. *PLOS Neglected Tropical Diseases*. 2020;14(12):e0008825.
2. Chandler DJ, Fuller LC. A review of scabies: an infestation more than skin deep. *Dermatology*. 2019;235(2):79-90.
3. CDC. Scabies [Internet]. 2010 [cited 2021 Jun 30]. Available from: <https://www.cdc.gov/parasites/scabies/disease.html>.
4. World Health Organization (WHO). Scabies [Internet]. 2020. Available from: <http://www.who.int/news-room/fact-sheets>.
5. Indonesian Health Research and Development Agency. Basic health research (RISKESDAS) 2013. Jakarta: Indonesian Health Research and Development Agency; 2013.
6. World Health Organization (WHO). Neglected Tropical Diseases: Scabies [internet]. 2019. Available from: <https://www.who.int/neglected-diseases/diseases/scabies-and-other-ectoparasites/>.
7. Wibianto A, Santoso ID. Prevalence of scabies patients at ciwidey health center, west java in a 5-year period (2015-2020): retrospective study. *Jurnal Impelenta Husada*. 2021;1(3):281-90.
8. Farid AFM, Wulan D, Busman H, Rahmayani F. Differences in knowledge about prevention of scabies disease between before and after health promotion in grade 7 MTS students at Madarijul Ulum Islamic Boarding School Bandar Lampung. *Medical Profession Journal Of Lampung*. 2019;8(2):1-10.
9. Sobirin MY, Mayasari D. Management of scabies in one-year-old girls with a family medicine approach. *Medula: Jurnal Profesi Kedokteran Universitas Lampung*. 2017;7(3):50-6.
10. Gustia R, Anas E. Factors associated with the incidence of scabies in the work area of the Lubuk Buaya Health Center, Padang City in 2015. *Jurnal Kesehatan Andalas*. 2018;7(1):51-8.
11. Sungkar S. Scabies: etiology, pathogenesis, treatment, eradication, and prevention. Jakarta: Badan Penerbit FKUI; 2016.
12. Jasmine IA, Rosida L, Marlinae L. The relationship between knowledge and attitudes about personal hygiene with behavior prevention of scabies transmission observational study on child prisoners in Class IIA Martapura Child Correctional Institution. *J Publ Kesehat Masy Indones*. 2016; 3(1).
13. Kang S, Amagai M, Bruckner AL, Enk AH, Margolis DJ, McMichael AJ, et al. *Fitzpatrick's Dermatology*. 9th Edition. USA: McGraw-Hill; 2017.
14. Mila-Kierzenkowska C, Woźniak A, Krzyżyńska-Malinowska E, Kałużna L, Wesółowski R, Poćwiardowski W, et al. Comparative efficacy of topical permethrin, crotamiton and sulfur ointment in treatment of scabies. *Journal of Arthropod-Borne Diseases*. 2017 Mar;11(1):1-9.