

RESEARCH ARTICLE

CHA-collagen implantation to increase alveolar bone density

Dody Setiawan^{*,**✉}, Poerwati Soetji Rahajoe^{***}, Cahya Yustisia Hasan^{***}

*Rokan Hulu Hospital, Riau, Indonesia

**Oral and Maxillofacial Surgery Specialty Program, Faculty of Dentistry, Universitas Gadjah Mada, Yogyakarta, Indonesia

***Department of Oral and Maxillofacial Surgery, Faculty of Dentistry, Universitas Gadjah Mada, Yogyakarta, Indonesia

*JI Syekh Ismail, Pasir Pangairan, Rokan Hulu, Riau, Indonesia; ✉ correspondence: drg.dodysetiawan@gmail.com

Submitted: 21st November 2018; Revised: 3rd December 2018; Accepted: 22nd May 2019

ABSTRACT

Tooth extraction is the common procedure in dentistry. This procedure causes a wound in teeth socket. Thus, the socket had to be secured to prevent over resorption of alveolar bone. This study used the third molar as a model to examine the third molar mandibular odontectomy routine procedure in oral and maxillofacial surgery. The new bone formation could be evaluated by radiographic examination. The aim of this study was to evaluate the effect of CHA-collagen implantation on the third molar mandibular bone density using 3D-CBCT to determine bone quality. The research was conducted by comparing extraction socket after the third molar mandible odontectomy, before and after graft material implantation. The subjects were divided into two groups. Group A consisted of six non-implanted subjects and group B consisted of six subjects with CHA-collagen implanted socket. Three dimensional CBCT evaluated alveolar bone density using pixel intensity at the socket area after odontectomy procedure and 10 weeks after. The result of t-test showed that CHA-collagen implanted socket had significantly higher pixel intensity than non-implanted group ($p=0,046$) until 10 weeks. Spearman test showed that the implanted CHA-collagen had a positive correlation with the increase of alveolar bone density ($p=0.028$; $r=0.860$) until 10 weeks. In brief, implantation of CHA-collagen increased bone density until 10 weeks.

Keywords: alveolar bone density; carbonate hydroxyapatite-collagen; 3D-CBCT

INTRODUCTION

Tooth extraction is the common procedure in dentistry, which causes a wound or a tooth socket. Tooth sockets after extraction need to be treated immediately to maintain alveolar bone because it will lead to resorption of alveolar bone margins.^{1,2}

This resorption can be inhibited by the use of graft material. Third molar mandibular odontectomy procedure often leads in an unpleasant consequence for the patient, including pain and an unstable second molar.^{3,4} Universitas Gadjah Mada (UGM) developed new materials resembling bones that contains CHA having a similar composition to inorganic bone structures. This material contains a component of denaturalized bone mineral and polymer with a composition of 50:50.⁵ The use of CHA-collagen for sockets preservation after extraction in humans shows that CHA-collagen reduce resorption from 40-60% during the first year to only 12.67%.⁶

Three dimensional cone beam computed tomography (3D-CBCT) has more advantages than the traditional 2-dimensional radiographs (OPG, periapical), which are commonly used in the previous studies, including providing a 3 dimensional imaging and higher resolution levels, to enable the vision of anatomical structure with high accuracy. Three dimensional cone beam computed tomography (3D-CBCT) has a lower radiation absorption dose than the conventional CT.^{7,8}

Evaluation of CHA used in alveolar teeth has been carried out by various methods, including OPG examination, with eight weeks and three months periode. However, the research on CHA-collagen graft materials using 3D-CBCT has never been done before. This study aims to determine the effect of CHA-collagen implantation of mandibular third molar teeth post odontectomy sockets with 3D-CBCT evaluation.

MATERIALS AND METHODS

This research was an experimental study on humans involving 12 research subjects. The study was held at UGM Prof. Soedomo Dental Hospital to do the odontectomy procedure and 3D-CBCT photos, starting from August to December 2017. Ethical clearance was obtained from the Faculty of Dentistry UGM (No.001168/KKEP/FKG-UGM/EC/2017).

The patients was selected as research subjects according to the determined inclusion criteria, patients aged 17-26 years, no systemic disease, who has mandibular third molar impacted teeth, class IIA or IIB (Pell and Gregory classification). All patients had signed an informed consent to undergo dental treatment and to have the result written for publication.

The implanted material in this study was CHA-collagen (Gama-CHA®), which would be assessed to see its effect on alveolar bone density in post-odontectomy sockets of the mandibular third molar teeth Class IIA or IIB. Bone density was measured using color gradations with Volux 3D dental CT (Genoray, Korea) machines, which were set at 85 kVp and 89 mAs for 16 seconds and then they were measured by Image J software. This software produced bone density value in the form of pixel intensity, indicated by levels of color gradation of each pixel. The color gradation takes the form of color patterns and figures in the region of interest (ROI), namely areas that focus on measuring pixel intensity in the post odontectomy area of the mandibular third molar in each circular sample, with an area of 113.448 mm².

The patients were divided into group A or B randomly. Patients with poor oral hygiene received periodontal treatment one week before the study and investigations in the form of radiographic images of OPG as a routine procedure before odontectomy.

Subjects in group A having tooth odontectomy were examined with the opening of the envelope flap from the distal third molar to the distal mandibular first molar. After the tooth was removed, it was debrided by removing the remaining soft tissue, having socket curettage, irrigating with 0.9% NaCl solution, and having the 3D-CBCT for the purpose

of determining initial ROI in mandibular third molar and measurement of alveolar bone density after odontectomy. Suturing was done with interrupted techniques without implantation of graft material.

Subjects in group B received tooth odontectomy treatment with the same procedure as those of group A, and their 3D-CBCT radiographic images were taken for the purpose of obtaining ROI and measurement of alveolar bone density after odontectomy and implantation of CHA-collagen graft material and sutured which was done with the same procedure as group A.

Patients were given post-odontectomy education after surgery procedures, the same medication, and suture removal on the 7th postoperative day, and then, patients were asked to come back after the 10th week post operatively to take the 3D-CBCT radiograph again. The 3D-CBCT radiographic taking procedure (Volux, Korea) was carried out in the postural sitting position with the patient's head positioned using a red beam from a CBCT machine, where horizontal rays paralleled the occlusion of the teeth and vertical rays on the midline of the face.

Exposure was done by single radiographer, then it was processed using imageJ software to obtain data in the form of pixel intensity that showed alveolar bone density after odontectomy. Measurement of the occurring pixel bone intensity was calculated by drawing a line or limiting the area in the desired area (ROI).^{9,10}

The 3D-CBCT after odontectomy (H_0) and 10 weeks after odontectomy ($H_{+10 \text{ weeks}}$) was taken in all subjects by a single radiographer. Pixel intensity calculations in each group on H_0 and H_{+10} weeks were carried out by a dental and maxillofacial radiology specialist. The results of the 3D-CBCT digital image could be calculated using pixel intensity using a particular software on the computer. The software could measure bone density by showing the quality of the bone, so in this study, 3D-CBCT radiographs were used. The 3D-CBCT could be used to examine the part that received donor graft material before and after surgery. The results of the interpretation of 3D-CBCT assess bone quality, because bone density is an indicator for bone quality.

RESULTS

The results of alveolar bone density calculation were in the form of pixel intensity values in each study sample as shown in Table 1. The calculation was performed in each of the same regions of interest (113.448 mm²) after the initial odontectomy (H₀) and after the 10th week (H_{+10 weeks}). The pixel intensity value shows the minimum, maximum and average values (mean) of each sample H₀ and H_{+10 weeks}. The number or value is a value on the interval scale and post odontectomy sockets volume are directly proportional to graft size. Results of radiographic CBCT photographs and determination of ROI in post-odontectomy sockets are shown in Figure 1.

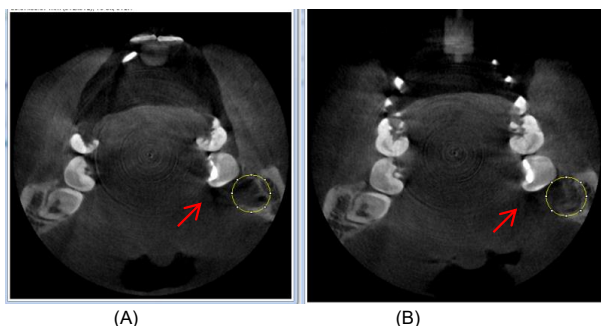


Figure 1. Photograph of pixel intensity reading on ROI on the same patient; before implantation of graft material (A) and after 10 weeks of implantation (B)

The highest mean in group A on H₀ was 392.18 and the lowest was 218.27, while the highest mean in group B was at 388.24 and the lowest

was 231.50. At H_{+10 weeks} the highest mean group A reached 577.89 and the lowest was 360.33, while group B had the highest mean of 644.29 and the lowest was 414.39. Overall, the mean of group A on H₀ was 304.15, relatively lower than group B (376.78). The increase in the average group A density on H₀ (304.15) rose to (455.72) at H_{+10 weeks} and in group B it increased from (376.78) to 569.34.

The comparative results of paired t-test (Table 2) showed that both group A and group B bone density at H_{+10 weeks} were higher when compared to H₀ significantly (p < 0.05). In other words, there was the same trend in both groups as indicated by an increase in bone density at H_{+10 weeks}. However, the correlation was only found in the group provided with the graft, indicating a correlation between the graft and increased bone density. Likewise, the Pearson correlation test (Table 2) revealed that graft implantation until the 10th week would increase bone density (p=0.028) significantly with a correlation coefficient of r=0.860. In words, there is a positive and strong correlation between initial alveolar bone density and after graft use.

The comparative results of the independent t-test (Table 2) on H₀ did not result in significant differences in density between group A and group B (p=0.197) because the graft material had not been implanted yet. Nonetheless, after H_{+10 weeks} it was found that the implanted graft group had a density that was significantly higher than the group without graft (p=0.046).

Table 1. Results of calculation of alveolar bone density

Group	No	ROI area	Starting point (H ₀ without graft)			10 weeks (H _{+10 weeks})		
			Min	Max	Mean	Min	Max	Mean
A	1	113.448	-20	1425	392.18	-191	1069	414.36
	2	113.448	-320	1470	334.34	-2	1594	524.77
	3	113.448	-465	1376	323.72	-3	1425	577.89
	4	113.448	-995	1447	226.24	-617	1528	470.63
	5	113.448	-319	1470	330.17	-273	1387	386.33
	6	113.448	-1000	1724	218.27	-1000	1522	360.33
B	1	113.448	-358	1374	388.24	-230	1216	414.39
	2	113.448	-275	1119	303.58	75	1293	633.37
	3	113.448	39	1927	415.52	25	1649	633.45
	4	113.448	-1000	1742	554.54	18	1374	644.29
	5	113.448	-540	1548	231.50	35	1268	536.63
	6	113.448	-50	1527	367.27	21	1543	553.91

Description: A: Group without implanted graft.

B: Group with implanted graft.

Table 2. Pair t-test results for each observation group, t-test test between observation groups, and correlation test

Observation	Group A (without <i>graft</i>)	Group B (with <i>graft</i>)	Df	p ³
	x ± SD	x ± SD		
H ₀	304.15 ± 68.07	376.78 ± 109.35	5	0.197
H+10	455.72 ± 84.31	569.34 ± 88.48	5	0.046*
p ¹	0.012*	0.000*		
p ²	0.688	0.028*		
r		0.860		

Description: P¹ : Comparative pair t-test
P² : Corelation pearson test
p³ : Comparative independent t-test
r : Correlation coefficient
* : significant α: 0.05

DISCUSSION

Tooth extraction is a commonly practiced procedure in the field of dentistry. This procedure causes a wound on the socket of the tooth. Tooth sockets need to be maintained to prevent excessive resorption of alveolar bone.^{1,2,4}

Bone matrix consists of organic, inorganic and water components, at the rate of 25%, 65% and 10%. The 90% organic component is collagen, while the inorganic component consists mainly of CHA. Both components are natural osteoconductive. Graft implantation material is produced from materials that have similar properties.¹¹

Research on the composition of CHA and collagen in in vivo has been carried out in relation to mechanical strength, microstructural observation, radiographic analysis and the formation of new collagen densities formed (Ana and Erwanto, 2013), but further studies in humans by Lutfianto et al (2017) and Sitanggang et al (2017) showed no increase in the expression of ALP and Osteocalcin mRNA after CHA-combination of collagen implantation in sockets without suturing after tooth extraction on the 3rd and 14th days with a limited number of samples of 4 subjects. This fact indicated the differences in results between animals and humans. On this basis, this study observed the implantation of CHA-collagen to assess bone density.^{5,12}

The mean pixel alveolar bone group intensity without graft 304.15 increased significantly to 455.72 at 10 weeks (p = 0.012). The same result occurred in the group with graft, indicated by the average pixel intensity of alveolar bone increase from 376.78 to 569, 34 to 10 weeks (p = 0.000) This significant increase means that with or without the provision of CHA-collagen graft, there was an increase in bone density up to 10 weeks.

Significant density differences between group A and group B at H₀ were not found (p = 0.197). This result had been predicted because both were empty sockets before implanted graft material. The group without graft at H_{+10 weeks} did not show a significant correlation with bone density (p = 0.688). Nonetheless, the group with graft had a significantly higher density than the group without graft (p = 0.046), and there was a significantly positive correlation (p = 0.028), with a correlation coefficient of r = 0.086. This value indicated that the role of graft contributed to increasing bone density.

The graft material in this study was CHA which was osteoconductive. This material plays a role in giving scaffold to facilitate the attachment of osteogenic material in the form of mesenchymal and growth factors originating from the periosteal in the scaffold. This process was followed by the chemotaxis process of the host mesenchyme

in the implanted area, then the differentiation of primitive cells from the host into the chondroblasts and osteoblasts, and the osteoblasts which would produce a matrix. In this process, the osteoblasts closing the matrix would become osteocytes which then reinforced the calcification process followed by the remodeling process.^{13,14} According to Wahl and Czernuszka (2006), CHA implantation from the beginning of the bone healing process will release calcium and phosphate, which can increase the precipitation of biological apatite (HA), mimicking the mineralization phase of the bone, so that the post-extraction process will be faster to form new bone with the application of CHA material.^{14,15}

Despite this finding, there was a relatively rare research to address the use of graft material in humans using radiographic examination. Therefore, this study was carried out using a CBCT radiographic examination in humans for 10 weeks according to the period of bone healing phase, ie the initial phase of 2-3 weeks mineralization. The process ended up with the final phase of remodeling 100 days after tooth extraction by considering exposure to radiation doses on radiographic CBCT.^{2,16,17}

On the same study of Panday et al. (2015) revealed an increase in alveolar bone density after mandibular third molar odontectomy for three months after implantation of CHA-collagen graft material. The result was then compared with sockets without implantation of graft material as a control. The CHA-collagen study with different observations was carried out by Vohra (2016) in terms of the length of observation ie at day 0 and 8 weeks. Using OPG in the mandibular third molar socket, the results showed a significant increase in alveolar bone density between groups of graft material implantation compared to groups without graft. It also indicated a visible formation of a completely new bone formation. The two studies showed that the combination of collagen CHA implantation for up to three months still showed an increase in bone density.^{15,18}

Haghighat et al. (2011) on post odontectomy of mandibular third molar without graft material at day 0, 2nd month, 4th month and 6th month, showed a significant increase in alveolar bone density at day

0 and up to two months. However, there was no significant difference at 4th months and 6th months.¹⁹ Sockets without graft material administration in this study were given for more than 2 months (10 weeks) and there was still an increase in bone density. Therefore, further research is needed to assess the time of increase in density between 10 weeks to 4 months. Digital imaging can be analyzed using two different images that look identical according to the naked eye, but differ according to pixel analysis. Images that look the same can consist of different pixel values, whereas images that look different can still consist of the same pixel value.^{20,21}

CONCLUSION

Based on the research and analysis, implantation of CHA-collagen increased bone density by up to 10 weeks. However, it is suggested that further studies multiply the number of research subjects to increase the validity of the study and the need for additional observation time to assess the optimum bone density formed after the implantation of the CHA-collagen.

REFERENCES

1. Fragiskos FD. Oral Surgery 2nd ed. Springer-Verlag, Berlin. 2012;121-140.
2. Kubilius M, Kubilius R, Gleiznys A. The preservation of alveolar bone ridge during tooth extraction. *Stomatologija*. 2012; 14(1): 3-11.
3. Bartee B. Extraction site reconstruction for alveolar ridge preservation. Part 2: membrane-assisted surgical technique. *J Oral Implantol*. 2001; 27(4): 194-197.
doi: 10.1563/1548-1336(2001)027<0194:ESRFAR>2.3.CO;2
4. American Association of Oral and Maxillofacial Surgeons. Bone Grafting After Removal of Impacted Third Molars 1sted, New York. 2013; 1-2.
5. Ana ID, Erwanto Y. Evaluation of osteoconductive capacity of bio-inspired carbonate apatite bone substitute in goat model. *Proceeding Book: International Symposium on Apatite and Correlative Biomaterials IV*. Nantes. 2013; 1-8.

6. Ana ID. Modul pengenalan singkat Gama-CHA your bone regeneration scaffold. Yogyakarta: UGM Press. 2014; 1-21.
7. Alamri HM, Sadrameli M, Alshalhoob MA, Sadrameli M, Alshehri MA. Applications of CBCT in dental practice: a review of the literature. *Gen Dent*. 2012; 60(5): 390-400.
8. Scarf WC, Farman AG. What is cone-beam CT and how does it work? *Dent Clin N Am*. 2008; 52(4): 707-730.
doi: 10.1016/j.cden.2008.05.005
9. Bankhead P. Analyzing fluorescence microscopy images with ImageJ. Queens University Belfast, <http://image.nih.gov/ij/images/>. 2014; 12-28.
10. Labno C. Basic Intensity Quantification with ImageJ. University of Chicago; 2015. 1-5.
11. Burr DB, Allen MR. Basic and Applied Bone Biology, 1sted. New York: Elsevier; 2014; 1-48.
12. Lutfianto B, Rahardjo, Rahajoe PS. Ekspresi mRNA osteokalsin pada soket pasca pencabutan gigi dengan pemberian bahan cangkok tulang carbonate-hydroxyapatite (Studi Eksperimental pada Manusia). *J Ked Gi*. 2017; 8(3): 280-286.
13. Nandi SK, Roy S, Mukherjee P, Kundu B, De DK, Basu D. Orthopaedic applications of bone graft and graft substitutes: a review. *Indian J Med Res*. 2010; 132: 15-30.
14. Ana ID, Matsuya S, Ishikawa K. Engineering of carbonate apatite bone substitute based on composition-transformation of gypsum and calcium hydroxide. *Engineering*. 2010; 2(5): 344-352.
doi: 10.4236/eng.2010.25045
15. Panday V, Upadhyaya V, Berwal V, Jain K, Sah N, Sarathi P, Swami PC. Comparative evaluation of G-Bone (Hydroxyapatite) dan G-Graft (Hydroxyapatite with Collagen) as bone graft material in mandibular III Molar Extraction Socket. *J Clin Diagn Res*. 2015; 9(3): 48-52.
doi: 10.7860/JCDR/2015/12140.5713
16. Madan R, Gupta V, Bains VK, Patil SS, Singh GP, Madan M. Socket preservation vis-a-vis natural healing: literatur review. *Asian Journal of Health & Allied Sciences*. 2011; 1(3): 195-201.
17. Oscandar F. Radiologi Kedokteran Gigi Aplikasi 3D-CBCT 1sted. Jakarta: EGC. 2013; 43-54.
18. Vohra A. Radiological measurement of bone density to assess the efficiency of bone graft. *IAIM*. 2016; 3(2): 88-91.
19. Haghighat A, Hekmatian E, Abdinian M, Sadeghkhan E. Radiographic evaluation of bone formation and density changes after after mandibular third molar extraction: a 6 month follow up. *Dent Res J (Isfahan)*. 2011; 8(1): 1-5.
20. Ferreira T, Rasband W. ImageJ User Guide: ImageJ/Fiji; 2012. 1-46, 149-154, <http://imagej.nih.gov/ij/features.html>.
21. Baecker V. Workshop: Image Processing and Analysis with ImageJ and MRI Cell Image Analyzer. Montpellier RIO Imaging; 2008. 7-8.