

Intracerebral and Subarachnoid Hemorrhage as a Result of Infective Endocarditis: A Case Report

Alviani Februana Waluyani Putri^{1*}, Jagaddhito Probokusumo¹, Wahyu Widjanarko², Ririn Faujiah²

¹Medical Doctor at R.S.U.D. Jombang, East Java, Indonesia

²Cardiologist at R.S.U.D. Jombang, East Java, Indonesia

*Corresponding author:

Alviani Februana Waluyani Putri, MD, - email: alvianifwp@gmail.com

R.S.U.D Jombang, East Java, Indonesia

Manuscript submitted: November 19, 2017; Revised and accepted: December 21, 2017

ABSTRACT

Infective endocarditis (IE) may have devastating and life-threatening neurological complications. The incidence of intracranial hemorrhage (e.g. subdural hematoma, subarachnoid hemorrhage (SAH), and intracerebral hemorrhage (ICH)) is rare. A 39 years old male, came to emergency unit with heart failure clinical features, accompanied with fever for 2 weeks, and apical systolic murmur found in the physical examination. In the second day of admission, the patient experienced a sudden decrease of consciousness, weakness of the right limbs, and slurred speech. CT scan examination showed left parietal lobe ICH with volume \pm 20 cc, and SAH in left parietal lobe, basal system, to pontine system. Echocardiography revealed AML flail with severe mitral regurgitation and vegetation in AML. Empirical parenteral antibiotics ceftriaxone and gentamicin were given. In the following day, the consciousness was increasing. Later, the blood culture examination showed growing of *Staphylococcus saprophyticus*. Intracranial hemorrhage may cause worsening in patient's condition, and require withdrawal in anticoagulant therapy. Cardiac surgery should be delayed. Despite of its uncommon incidence, physician should be aware of the neurological complication of IE to recognize and do the prompt treatment of the disease.

Keywords: infective endocarditis; intracerebral; subarachnoid hemorrhage

INTISARI

Endokarditis infeksi (EI) dapat menimbulkan komplikasi neurologis yang dapat mengancam nyawa. Insiden dari perdarahan intrakranial (yaitu hematoma subdural, perdarahan subaraknoid (SAH), dan perdarahan intraserebral (ICH)) sangat jarang terjadi. Seorang laki-laki 39 tahun datang ke unit gawat darurat dengan gejala klinis gagal jantung, disertai dengan demam selama 2 minggu, dan murmur sistolik di apeks ditemukan dalam pemeriksaan fisik. Pada hari kedua rawat inap, pasien mengalami penurunan kesadaran mendadak, kelemahan pada tubuh sebelah kanan, dan bicara pelo. Hasil pemeriksaan CT scan menunjukkan adanya ICH di lobus parietal kiri dengan volume \pm 20 cc, dan SAH di lobus parietal kiri, sisterna basalis dan sisterna pontine. Ekhokardiografi menunjukkan adanya AML flail dengan mitral regurgitasi berat dan vegetasi di AML. Antibiotik parenteral empiris yaitu ceftriaxone dan gentamisin diberikan pada pasien. Hari berikutnya, kesadaran pasien mulai meningkat. Hasil dari kultur darah menunjukkan pertumbuhan *Staphylococcus saprophyticus*. Perdarahan intrakranial dapat menyebabkan perburukan dari kondisi pasien, dan penggunaan terapi antikoagulan sebaiknya dihentikan. Operasi jantung juga sebaiknya ditunda. Walaupun insidensinya tidak banyak, dokter harus mengetahui komplikasi neurologis dari IE untuk dapat mengenali dan memberikan terapi yang tepat.

INTRODUCTION

Infective endocarditis (IE) is still a major clinical problem due to its high morbidity and mortality rates. Its various complications could worsen the patients' condition especially neurological complications. Neurological complications that manifests into symptoms happen in approximately 15-30% of patients of IE.^{1,2} It ranges from ischemic stroke or TIA, cerebral hemorrhage, cerebral microbleeds, cerebral abscess, mycotic aneurysms, meningitis, and toxic encephalopathy with embolic cases as the most frequent,³ those neurological diseases were described as the presenting symptom in 47% cases,³ with an embolic event as the most frequent manifestation (23/55; 42% Cerebral hemorrhage occur in 12-30% of neurological complication in IE.^{1,3} In our knowledge subarachnoid hemorrhage (SAH) and intracerebral hemorrhage (ICH) in IE are uncommon, and rarely reported happen in the same patient in case presentation.

Neurological complications could affect the choice of treatment for IE. The management of IE requires combination of medical and surgical approach, the benefit and the risk have to be balanced to choose the prompt therapy.⁴ In some cases the indication of cardiac surgery remained, meanwhile in other cases the poor neurological prognosis delayed the surgery.⁴

This case report describes the case of ICH and SAH as the complication of IE and discuss the management of the case compared with the guideline.

CASE PRESENTATION

A 39 years old male came to emergency department with shortness of breath especially after walking in a distance and also when lying down sleeping one week before admission. He often woke up at night because of the shortness of breath and more comfortable in sitting position.

He suffered from cough with white sputum and swelling of both legs. Two weeks before admission he had low grade fever. He also felt stomach discomfort and joint pain. The patient didn't have history of similar symptoms before, no chest pain, and no history of hypertension. History of intravenous drug use, or predisposing heart condition such as prosthetic valve surgery were also denied.

In physical examination, the patient was compos mentis with GCS 4/5, blood pressure 111/84 mmHg, heart rate 126 bpm, respiratory rates 25 times per minute, with temperature 37.1 °C. Systolic murmur was found in the apex, and he had leg edema. Laboratory examination revealed slight decrease of hemoglobin (10.4 g/dl), rise of platelet (439.000/ μ l and AST level (54 U/L), the other were within normal limitation.

Thorax x-ray was performed and showed bilateral pleural effusion and slight cardiomegaly. Electrocardiogram (ECG) revealed sinus rhythm 120 bpm with occasional ventricular extrasystole (VES). The patient was assessed with heart failure NYHA functional class II and suspect mitral regurgitation. Ringer lactate infusion

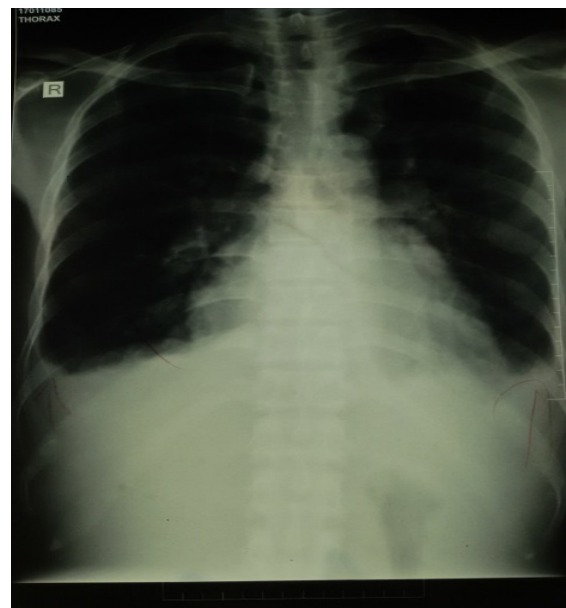


Figure 1. Thorax x ray examination showed bilateral pleural effusion and slight cardiomegaly

500 cc /24 hours, furosemide 20 mg injection, and omeprazole 40 mg injection were given. Abdominal ultrasonography was performed and revealed no abnormality in the abdomen.

In the second day of admission, patient had fever with 39°C body temperature. White blood cell increased (17.300/ μ l). ECG examination showed anteroseptal ischemia however the CKMB was within normal limit. Paracetamol 500 mg tid, isosorbide dinitrate 5 mg tid and clopidogrel 75 mg once a day were planned to be given, when suddenly the patient had decrease of consciousness with Glasgow Coma Scale 3-2-5 and slurred speech. There were right facial palsy, and right lateralization. Non contrast head CT scan revealed ICH at left parietal lobe with perifocal edema causing midline shift 0.6 cm to the right, and SAH in left parietal, basal system, until pontine system. The patient was moved to high care unit. Neurologist consultant suggested intravenous piracetam 3 gram injection tid, nimodipine 60 mg oral qid, and metamizole injection tid. Clopidogrel administration was delayed and intravenous ceftriaxon 1 gram bid was given.

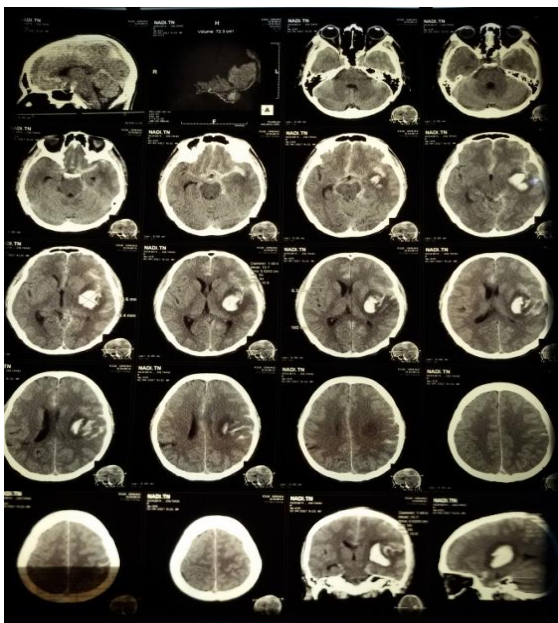


Figure 2. ICH and SAH in left parietal lobe shown in CT scan examination

In the following day, echocardiography was performed and showed severe mitral regurgitation, anterior mitral leaflet (AML) flail with Vmax 4.90 m/s, trivial tricuspid regurgitation, normal left ventricle, slight left ventricle hypertrophy, and vegetation in AML. Systolic and diastolic function of left ventricle was normal with ejection fraction (EF) by Teich 67.08% and mitral E/A ratio 1.97. Renal function test revealed normal serum creatinine and ureum. Intravenous gentamicin injection 80 mg bid was added in the therapy. In the next day, the consciousness improved with GCS 4-4-6, however the blood pressure dropped into 90/50 mmHg. Intravenous dopamin 5 meq was given to the patient and nimodipine was stopped. After that the patient's blood pressure rose into 110/80 mmHg and the dopamin was withdrawn after 2 days. The patient also had hematuria, however urinalysis did not manage to be performed. Later, the blood culture result was the growing of *Staphylococcus saprophyticus* which was sensitive to linezolid, tigecyclin, nitrofurantoin, rifampicin, and trimethoprim/sulfamethoxazole. Unfortunately, the patient did not want to continue to receive treatment in hospital due to financial problem.

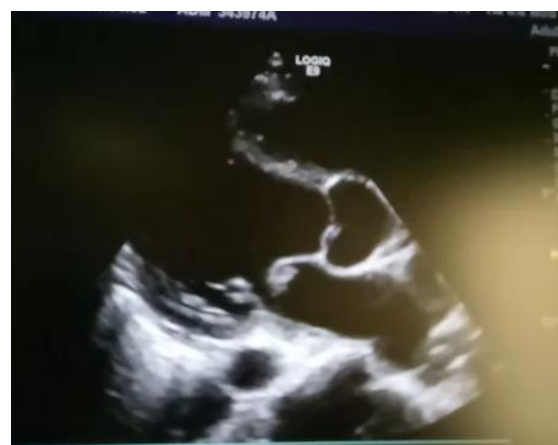

Figure 3. Transthoracal echocardiography showed vegetation in AML

DISCUSSION

We reported a case of male patient, 39 years old with IE presented with heart failure (HF) manifestation accompanied by fever. In the second day of admission, the patient had a sudden decrease of consciousness caused by ICH and SAH. The diagnosis of IE was established through applying Dukes criteria with 1 major and 3 minor criteria. One major criterion fulfilled as the echocardiography examination showed vegetation in AML. Three minor criteria was fever with temperature $> 38^{\circ}\text{C}$, vascular phenomena which was intracranial hemorrhage, and positive blood culture but did not meet a major criterion.⁴

Heart failure is the most frequent complication found in IE⁵, mainly caused by a new or worsening of valve regurgitation such as aortic or mitral valve.⁶ In this patient systolic murmur in apex of the heart was found in the physical examination, so the mitral regurgitation was suspected. Then, in echocardiography, the severe mitral regurgitation was confirmed with normal function of left ventricle. We still did not know whether the valve regurgitation was new or already happened for a long time. Patients who develop acute severe mitral regurgitation usually present with symptomatic heart failure because the ventricles are fail prepared to accept the sudden increase in volume load. If the patient survives the acute episode or has slowly progressive worsening of mitral regurgitation, the symptoms are therefore either absent or slowly progressive over any years. The adaptive changes of the ventricle to the volume overload include left ventricle dilatation and eccentric hypertrophy. However decompensation may eventually develop if the regurgitation is sufficiently severe.⁷

Neurological complications in IE, stroke in particular, are associated with higher mortality and morbidity.^{1,3} The pathological mechanism of intracranial bleeding are wide ranging, from

the hemorrhagic conversion of infarcted area secondary to septic emboli, rupture of intracranial mycotic aneurysms (ICMA), until microbleeds due to immunologic vasculitis.⁸⁻¹⁰

SAH in IE is uncommon and only described in case reports. ICMA is classically associated with SAH, however non-aneurysmal spontaneous SAH could happen in a rare cases.^{9,11} American Heart Association (AHA) recommends computed tomographic angiography (CTA) and magnetic resonance angiography (MRA) to examine the patient with neurological symptoms to detect cerebral aneurysm.¹² ICH in IE also can be the result of arterial injury, such as septic arteritis that usually occurs during uncontrolled infection.¹³ In this case, a very rare ICH and SAH were happened at the same time in the left parietal lobe area. However, further studies to know what caused the bleeding could not be done due to the limitation of the resources.

The general principle of successful treatment of IE relies on microbial eradication by anti-microbial drugs. Surgery contributes by removing infected material and draining abscesses.⁴ Early diagnosis and administration of appropriate antibiotics are also important in preventing neurological complication.¹⁴ Empirical treatment should be started promptly before the blood culture result out. For choosing the empirical antibiotic several things had to be considered such as previous antibiotic therapy, native or prosthetic valve, and local epidemiology of antibiotic resistance.⁴

Proposed antibiotic regimens for initial empirical treatment for native valves were ampicillin with (flu)cloxacilin or oxacilin with gentamicin (class IIa, level C), or vancomycin with gentamicin (class IIb, level C).⁴ In this patient, ceftriaxone with gentamicin were given based on the antibiotic resistance mapping in our hospital. Later, the culture showed *Staphylococcus saprophyticus* sensitive to linezolid, tigecyclin, nitrofurantoin, rifampicin, trimethoprim/

sulfamethoxazole. In the guideline for coagulase negative staphylococci, cotrimoxazole combined with clindamycin were recommended (class IIb, level C)⁴ and it matched with the result of blood culture. Appropriate antibiotics should be given but unfortunately the patient did not want to continue receiving care at hospital so the physician could not monitor the administration of the drugs and the patient's outcome.

Heart surgery is indicated in IE patient with HF symptoms especially in the cases that caused by severe aortic or mitral regurgitation.⁴ However, in patients with HF functional class I or II with severe valvular regurgitation and no other reasons for surgery, antibiotic administration under strict clinical and echocardiographic observation is a good option, although early surgery may be an option in selected patients at low risk for surgery.⁴ Based on the recommendation, intracranial hemorrhage also made the surgery should be delayed for at least 1 month (class IIa, level B).⁴ In IE patients with neurological complications, clinical assesment, cerebral CT scan or MRI and echocardiography should be done to detect the comorbidity such as heart failure, uncontrolled infection, abcess, and risk of embolism. If those factors are present, the severe neurological complications are being assessed including intracranial haemorrhage, coma, severe comorbidities, or stroke with severe damage. If there is no severe neurological complications, heart surgery is considered. Otherwise if there are comorbidities and severe neurological complications, conservative treatment and monitoring should be performed.⁴ So in this patient, the cardiac surgery was not indicated at that time.

The recommendations for management of anticoagulant therapy in IE patients are based on low level evidence. Study stated that consuming anticoagulant during IE development may diminish early embolic tendencies.¹⁵ However, in intracranial hemorrhage, interruption of all anticoagulation is recommended (class I, level C).⁴

CONCLUSION

Neurological complications might present in IE with higher morbidity and mortality. The rare form of neurological complications, intracranial hemorrhage, may cause worsening in patient's condition, and require withdrawal in anticoagulant therapy. Cardiac surgery should be delayed. Despite of its uncommon incidence, physician should be aware of the neurological complication of IE to recognize and do the prompt treatment of the disease.

REFERENCES

1. García-Cabrera E., Fernández-Hidalgo N., Almirante B., Ivanova-Georgieva R., Nouredine M., Plata A., et al. 2013. Neurological complications of infective endocarditis risk factors, outcome, and impact of cardiac surgery: A multicenter observational study. *Circulation*, 127:2272–2284.
2. Murdoch D.R., Corey G.R., Hoen B., Miró J.M., Fowler V.G. Jr., Bayer A.S., et al. 2013. Clinical presentation, etiology and outcome of infective endocarditis in the 21st century: The International Collaboration on Endocarditis-Prospective Cohort Study. *Arch Intern Med*, 169:463–473.
3. Heiro M., Nikoskelainen J., Engblom E., Kotilainen E., Marttila R., Kotilainen P. 2000. Neurologic manifestations of infective endocarditis: a 17-year experience in a teaching hospital in Finland. *Arch Intern Med*, 160:2781–2787.
4. Habib G., Lancellotti P., Antunes M.J., Bongiorni M.G., Casalta J.P., Del Zotti F., et al. 2015. 2015 ESC Guidelines for the management of infective endocarditis. *Eur Heart J*, 36:3075-3128.
5. Tornos P. 2005. Infective endocarditis in Europe: lessons from the Euro heart survey. *Heart*, 91:571–575.

6. Anguera I., Miro J.M., Vilacosta I., Almirante B., Anguita M., Muñoz P., et al. 2004. Aorto-cavitary fistulous tract formation in infective endocarditis: clinical and echocardiographic features of 76 cases and risk factors for mortality. *Eur Heart J*, 26:288–297.
7. Maganti K., Rigolin V.H., Sarano M.E., Bonow R.O. 2010. Valvular heart disease: diagnosis and management. *Mayo Clin Proc*, 85:483–500.
8. Klein I., Lung B., Labreuche J., Hess A., Wolff M., Messika-Zeitoun D., et al. 2009. Cerebral microbleeds are frequent in infective endocarditis: A case-control study. *Stroke*, 40:3461–3465.
9. Novy E., Sonnevile R., Mazighi M., Klein I.F., Mariotte E., Mourvillier B., et al. 2013. Neurological complications of infective endocarditis: New breakthroughs in diagnosis and management. *Médecine Mal Infect*, 43:443–450.
10. Morotti A., Gamba M., Costa P., Poli L., Gilberti N., Delrio I., et al. 2016. Infective endocarditis presenting with intracranial bleeding. *J Emerg Med*, 51:50–54.
11. Chukwudelunzu F.E., Brown R.D., Wijdicks E.F.M., Steckelberg J.M. 2002. Subarachnoid haemorrhage associated with infectious endocarditis: case report and literature review. *Eur J Neurol*, 9:423–427.
12. Baddour L.M., Wilson W.R., Bayer A.S., Fowler V.G.Jr., Tleyjeh I.M., Rybak M.J., et al. 2015. Infective endocarditis in adults: Diagnosis, antimicrobial therapy, and management of complications: A scientific statement for healthcare professionals from the American Heart Association. *Circulation*, 132:1435-1486.
13. Aziz F., Perwaiz S., Penupolu S., Doddi S., Gongireddy S. 2011. Intracranial hemorrhage in infective endocarditis: A case report. *J Thorac Dis*, 3:134–137.
14. Dickerman S.A., Abrutyn E., Barsic B., Bouza E., Cecchi E., Moreno A., et al. 2007. The relationship between the initiation of antimicrobial therapy and the incidence of stroke in infective endocarditis: An analysis from the ICE Prospective Cohort Study (ICE-PCS). *Am Heart J*, 154:1086–1094.
15. Snygg-Martin U., Rasmussen R.V., Hassager C., Bruun N.E., Andersson R., Olaison L. 2011. Warfarin therapy and incidence of cerebrovascular complications in left-sided native valve endocarditis. *Eur J Clin Microbiol Infect Dis*, 30:151–157.