

Histologic Features Of Catecholaminergic Neurons In the Substantia Nigra Pars Compacta Of Rat after Treated By Paraquat Dichloride For 12 Weeks

Tri Wahyu Pangestiningih^{1*}, Hery Wijayanto¹, Dwi Cahyo Budi Setiawan²

¹Anatomy Department, Faculty of Veterinary Medicine. Universitas Gadjah Mada, Jl. Fauna no.2, Universitas Gadjah Mada, Yogyakarta

²Pharmacology Department, Faculty of Veterinary Medicine, Universitas Gadjah Mada, Jl. Fauna no.2, Universitas Gadjah Mada, Yogyakarta

*Email: estifkh@ugm.ac.id

Received: July 3, 2020, Accepted: August 26, 2020, Published: September 1, 2020

Abstract

Paraquat dichloride is a herbicide to eradication wild grass that has a putative risk factor for Parkinson disease, a disease due to disruption of dopamine production at substantia nigra pars compacta as a part of mesencephalon. The exact dosage of paraquat dichloride that capable to cause the histological changing of catecholaminergic neuron for long time exposure is not determined yet. The aim of the research was to find out histological features of catecholaminergic neurons in the substantia nigra pars compacta after treated by paraquat dichloride for 12 weeks. Sixty adult male rats were divided into 6 groups, 5 rats each group. Group I (control) were injected by aquabidest. Group II – VI were injected respectively by paraquat dichloride 2.5; 5; 7.5; 10; and 12.5 mg/kg bw intraperitoneally, once a week for 12 weeks. One day after last injection, rats were sacrificed according to animal welfare, perfused intracardially in 10% buffered formalin. The brains were processed for histology in paraffin section. First section were histochemistry stained using cresyl violet and the next section were immunohistochemistry stained using tyrosine hydroxylase antibody as a marker of dopaminergic neurons. The results showed that dopaminergic neurons in substantia nigra pars compacta were bipolar and multipolar in shape; at dosages 10-12.5 mg/kg bw were less intense of tyrosine hydroxylase immunoreactivity and the cell membrane were disintegrated. In conclusion, the injection of paraquat dichloride at dosages 10 to 12,5 mg/kg bw once a week for 12 weeks caused degeneration of dopaminergic neurons in substantia pars compacta of rat.

Key words: degeneration; dopaminergic neuron; paraquat dichloride; Parkinson disease; substantia nigra pars compacta

Introduction

Agricultural modernization during the last 2 decades have been increasing sharply the use of herbicide in the farmer field. One of widely used herbicide is paraquat dichloride, a non-selective contact herbicide that suggesting could destroyed catecholaminergic neuron of the brain that caused Parkinson's disease. In our study, we would like to explore the effect of paraquat dichloride by observe the dopaminergic neurons in substantia nigra pars compacta as the main target cell that histological changes in Parkinson's disease.

Paraquat dichloride (*1,1 'dimethyl-4,4' bipyridinum dichloride*), is popular herbicide because very potent as phytotoxic (Gupta, 2007). The increased of paraquat dichloride (PQ) utilization, about 48% of total pesticide used in farm industry is believe to trigger some disease for farmer. Toxic effect of paraquat for catecholaminergic neuron in the substantia nigra is mimic to MPTP. According to Uversky, 2004; Miller, 2007, PQ capable to penetrate the brain-blood barrier and reach dopaminergic neuron, and causes the eventual destruction this cellsof subpopulation. The hypothesized that the cellular

mechanism of PQ toxicity, when this agent enter the neuron, it will be break down into component similar to a MPP⁺ metabolite that toxic to neurons dopaminergic's mitochondria at substantia nigra pars compacta, causing oxidative stress to the cells.

Parkinson's disease is one of neurodegenerative disease suffered by many elderly due to the damage of dopaminergic neuron in the substantia nigra pars compacta (Uversky, 2004), or disruption of nigro-striatal pathway (Betarbed, 2002) with the clinical sign: tremor, bradykinesia, hypokinesia and imbalance of movement (Emborg, 2004). Due to the limited treatment of the disease, we need to conduct a comprehensive study to prevent and treat Parkinson's disease.

Nigro-striatal pathway is dopaminergic pathway formed by neurons which produce dopamine neurotransmitter in substantia nigra pars compacta and their axon are projected to striatum. The existence of tyrosine hydroxylase (TH) in substantia nigra can be used as a marker of Catecholaminergic neurons, since this enzyme is required for dopamine synthesis (Reiner 1994; Ong et al., 2011).

In the previous studies showed that injection of paraquat dichloride with doses 5 - 15 mg / kb bw intraperitoneally, once a week for 6 weeks in *rattus norvegicus albinus* has declined the density and size of catecholaminergic neurons in substantia nigra. The rats body condition were weak and their hair become dull at the end of treatment (Pangestinarsih et. al., 2014). Because most of Parkinson's occurred chronically so we need to doing advanced research with dose less than 15 mg/kg bw paraquat dichloride, but in longer time period (12 weeks). From the research we expected new information about doses and the safe period of time related with the use of paraquat dichloride in the fields, in order to avoid Parkinson's disease. Rat is recommended as model the animal for Parkinson disease (Bertabet, 2002; Hau and Van Hoosier , 2005) also mice (Iddo Magen and Chesselet, 2010).

The aim of the study was to observe the histologic features of catecholaminergic neurons in the substantia nigra pars compacta, as an indicator of Parkinson's disease due to chronic treatment of paraquat dichloride in rat.

Material and Method

Sixty female rat (*Ratus norvegicus albinus*), 3.5 months old were divided into 6 groups. Group I (control) was treated with aquabidest sterile (PT Ikapharmindo Putramas, Reg Nu: GLK720932124341) injection intraperitoneally. Groups II – VI were treated with PQ (*1,1'dimethyl-4,4'bipyridinium*) (Gramozone 276 SL, PT. Surya Nusa, Reg. Nu: RI. 010301197436) to induce Parkinson's disease, in dosages respectively: 2,5; 5; 7.5; 10; and 12,5 mg/kg bw, intraperitoneal injection, once a week for 12 weeks.

Sample collection

A day after the last treatment, the rats were sacrificed humanly using combination of ketamine (PT Ikapharmindo Putramas, Cat. Nu: 51000000-OBC-000464110, 2-(2-chlorophenyl)-2-(methylamino)cyclohexan-1-one;hydrochloride) (20 mg/kg bw) and xylazine (Interchemie, Product code: IX2, 2 (2,6-dimethylphenylamino)-4H-5,6-dihydro-1,3-thiazin) (2 mg/kg bw), then were perfused intracardially using NaCl 0.9% (Otsu-NS, Cat. Nu: DKL9818705149A1) as the prerinse solution, followed by 10% buffered-formaline (Merck, Cat. Nu: 104003) for fixative solution. Rat brain were removed and processing for histology preparation in paraffin section. For histochemistry and immunohistochemistry staining, the brains were cut using rotary microtome in 12 µm thick. Method for euthanized rats was approved by ethical clearance committee of Gadjah Mada University, No: 133/KEC-LPPT/VII/2013.

Histochemistry and immunohistochemistry

Histochemistry staining of Nissl neuron were done using cresyl echt violet based on Kiernnan's (2008) method, while immunohistochemistry staining for TH were done as follow:

Endogen peroxidase were blocked in 3% H₂O₂ for 30 minutes. The slides then were drops with Revealit Antigen solution and incubated at 37°C overnight.

In the next morning, the tissue were rinse 4 time in PBS solution, 10 minutes each. The background were blocked using sniper (Medical, Cat Nu: STUHRP700) for 15 minutes at room

temperature. Primary antibody *rat anti-TH mouse serum* (1/2500; ImmunoStar, Cat. Nu: 22941) were applied to all slides except for control negative of immunohistochemistry staining that didn't receive primary antibody. The slide then were align horizontally in the moistured box, closed thigly and incubated for 4 nights at 4°C. After 4 nights incubation, the slide then were rinse using PBS 4 time, 15 minutes each. Secondary antibody-Trekkie Universal Link (Medical, Cat No: STUHRP700) was applied for 20 minutes before rinse 4 time in PBS for 15 minutes each. After rinsed, TrekAvidin-HRP (Medical, Cat Nu: STUHRP700) was applied for 10 minutes, and then the slides were rinsed using PBS 3 time for 15 minutes each. The slides were incubated using Betazoid DAB (Medical, Cat Nu: STUHRP700) solution for 5 minutes. Hematoxyline was use as counterstained for 30 seconds. After that, rinse the slide in aquadest for 3 time then were using for 30 seconds. After dehydration process in graded alcohol, slides then were cleared in xylene and mounted using canada balsam.

Observation and analysis

Slides were observed under light microscope, captured and the files were saved for descriptively analisys. Descriptive analisys were focused on the morphology, histological changes, staining intensity of catecholaminergic neuron in the substantia nigra pars compacta.

Results And Discussion

Substantia Nigra Pars Compacta Position in Rat's Mesencephalon

Substantia nigra is located in the ventral of mesecephalon, divided into pars compacta (SNc) and pars reticulata (SNr). In the fresh encephalon, area is appear as black area. Using cresyl violet staining, neuron appear as bluish purple (Figure 1A). Immunohistochemical staining using TH enzyme, SNc area is immunoreactive (TH-ir) (Figure 1B).

Immunohistochemistry staining in the adrenal gland as a control organ to test the accuracy of

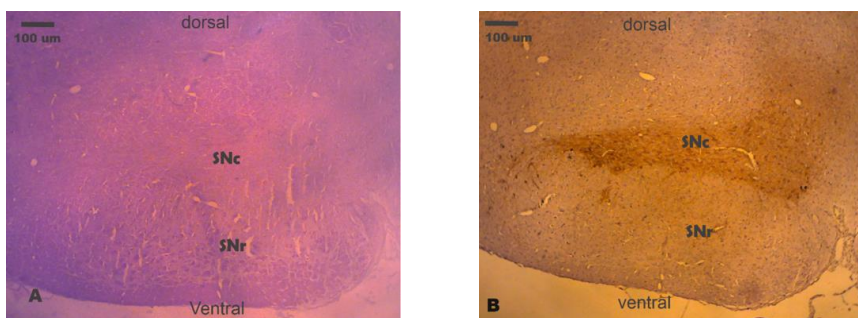


Figure 1. Area of substantia nigra of *Rattus norvegicus albinus* injected by 7,5 mg/kg bw paraquat dichloride intra peritoneally, once a week for 12 week. Substantia nigra is composed of 2 part, pars compacta (SNc) and pars reticulata (SNr). Using cresyl violet staining, neuron appear purple in color (A), while using immunohistochemistry using TH antibody show that SNc area is imunoreactive to the tyrosine hydroxylase enzyme (B). Scale bar: 100 µm

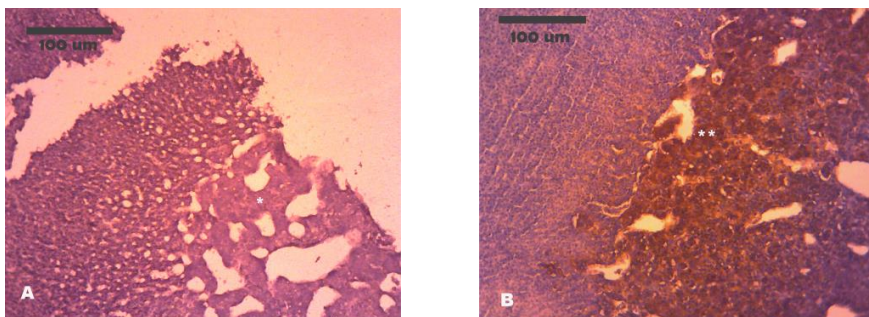


Figure 2. Rat's adrenal gland (*Rattus norvegicus albinus*) as a control for immunohistochemistry staining. A. Negative control, have no TH immunoreactive cells (*). B. Positive control, at medulla is found TH immunoreactive cells, brown in color (**). Scale bar: 100 µm

a IHC staining technique shows that the control negative (tissue without primary antibody) have no TH-ir cell, while positive control (tissue were given primary antibody) in the medulla area is TH-ir as displayed in Figure 2.

Neurons Catecholaminergic in Substantia Nigra pars compacta of the Rat that Injected by Paraquat Dichloride

Catecholaminergic (CA) neurons are distributed in the SNc either on the control and treatment rat. Morphology of CA neurons in such area are multipolar and bipolar.

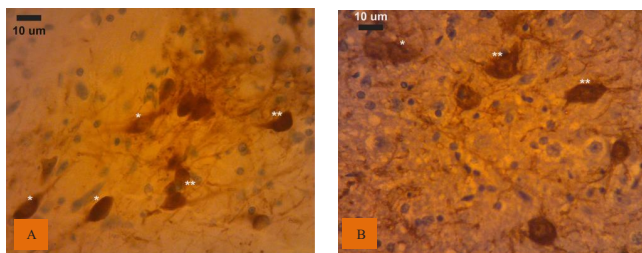


Figure 3. Neuron catecholaminergic in rat substantia nigra pars compacta of control without paraquat dichloride (A) and injected using 7,5 mg/kg bw paraquat dichloride intraperitoneally, once a week for 12 weeks (B). Catecholaminergic neurons are bipolar (*) and multipolar (**) in shape, with high intensity to TH antibody. Scale bar: 10 μm.

Treatment of rat at dosege of paraquat dicloride 2.5 - 7.5 mg/kg bw (Group II - IV) show staining intensity to TH as strong as the control (Group I), which indicates that the process of TH synthesis in CA neuron remain normal (Figure 3).

Microscopic change of CA neuron is observed in the rat group who injected 10 mg/kg bw of paraquat dichloride (Group V) and 12.5 mg/kg bw (Group VI). The observed change are the weakening are weakening of staining intensity to TH and reduced of membrane cells integrity. In the Group VI, neurons with no TH in the cytoplasm are found/observed, although it's cell membrane is imunoreactive (Figure 4).

Treatment paraquat dichloride 10 - 12.5 mg/kg bw in rat suggested causing disruption of TH synthesis process indicated by the decrease in the intensity of staining against TH. Our finding is relevant with the previous study by Chiccheti et al., (2005) that showed the decreasing of TH imunoreactivity in mice substantia nigra induce by paraquate dichloride. The CA neurons that showed

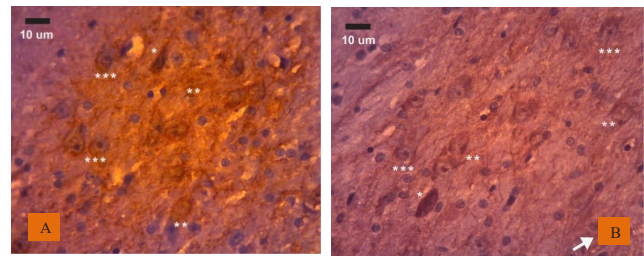


Figure 4. Substantia nigra of the rat (*Rattus norvegicus albinus*) injected with 10 mg/kg bw (A) and 12.5 mg/kg bw (B) of paraquat dichloride intraperitoneally, once a week for 12 weeks.

- A: Catecholaminergic neuron with high color intensity (*); weak intensity (**) and some neurons experincing cell membrane disintegration (***)
- B: Catecholaminergic neuron with high color intensity (*); weak intensity (**) and some neurons experincing cell membrane disintegration (***) and some neurons where the membrane are immunoreactive, while the cytoplasm non-immunoreactive (arrow). Scale bar: 10 μm.

disintegrity of cell membrane and weakness of TH imunoreactivity are indicated as cell degeneration process. Non imunoreactive cytoplasm with membrane cell still TH imunoreactive in rats that injected 12.5 mg/kg bw paraquat dichloride, might be CA neurons within SNc is experincing cell death.

Toxicity of PQ against cells involved redox cycling and production of reactive oxygen species (ROS), a free radical, that lead to oxidative stress (Ray et. al., 2007; Berry et. al., 2010). The ROS, especially O₂- and H₂O₂, able to cause damage to biological substance include nucleic acid and amino acid (Chance et. al., 1979). However, the most destructive effect of free radicals was induction of lipid peroxidation (Repetto et. al., 2012). Plasma membrane, that composed by phospholipid bilayer was the main target for ROS, which caused cell death. According to Bertabet (2002), paraquat capable to penetrate the brain-blood barrier, break down into a MPP⁺ metabolite that toxic to neurons dopaminergic's mitochondria at substantia nigra pars compacta, causing disruptions the process of cell's respiration and the cells experinced oxidative stress that lead to reactive oxygen. Further study on the incident of the cells death is needed by observe the cells that experinced apoptosis due to oxidative stress .

Based on the clinical symptoms, the treatment rats were have no sign of typical Parkinson's disease such as tremor, stiffness movement, and

difficulty to move. This could be happened because the body still strong enough to compensate some damage cells.

Conclusion

Injection of 2.5 - 7.5 mg/kg bw paraquat dichloride intraperitoneally, once a week for 12 weeks in the white rat did not cause any histological changing of neurons Catecholaminergic in the substansia nigra pars compacta, while 10 - 12.5 mg/kg bw caused degeneration as showed by decreased of tyrosine hydroxylase staining intensity and cell membrane disintegration.

Acknowledgement

With the completion of our research, we would like to thank to the Universitas Gadjah Mada for the funds and facilities provided.

References

- Berry, C., Vecchia, C.L., and Nicotera, P. 2010. Paraquat and Parkinson's disease. *Cell Death and Differentiation*. 17: 1115-1125.
- Betarbet, R., Sherer, TB. and Greenamyre, JT. 2002. Animal models of Parkinson's: Review articles. *Bioessays*. 24(4):308-18.
- Chance, B., Sies, H., and Boveris, A. 1979. Hydroperoxide metabolism in mammalian organs. *Physiological Reviews*. 59: 527-605.
- Cicchetti, F. 2005. Systemic exposure to paraquat and maneb models early Parkinson's disease in young adult rats. *Neurobiol Dis*. 20(2): 360-71.
- Dinis-Olivera, R.J., Remiao, F., Carmo, H., Duarte, J.A., Navarro, A.S., Bastos, M.L. and Carvalho, F. 2006. Paraquat exposure as an etiological factor of Parkinson's disease. *Neurotoxicology*. 27(6): 1110-22.
- Emborg, ME. 2004. Evaluation of animal models of Parkinson's disease for neuroprotective strategies. *J Neurosci Methods* 139(2): 121-43.
- Gupta, R. S. 2007. *Veterinary Toxicology: Basic and Clinical Principles*. Elsevier. Kentucky-USA. Pp 563-576
- Hau, J and Van Hoosier G L. 2005. *Handbook of Laboratory Animal science Second Edition. Volume III animals Models*. GRC press. New York.
- Magen, I. and Chesselet, M.F. 2010. Genetic mouse models of Parkinson's disease: The state of the art. *Prog Brain Res*. 184:53-87.
- Kiernan JA (2008) *Histological and Histochemical Methods : Theory and practice*, 4th ed. Bloxham, UK.
- Miller, G.W. 2007. Editorial. Paraquat: The Red Herring of Parkinson's Disease Research. *Toxicol Sci*. 100(1), 1-2.
- Pangestiningih, T.W., Wendo, W.D., Selan, Y.N., Amalo, F.A., Ndoang, N.A. and Lenda, V. 2014. Histological Features of Catecholaminergic Neuron in Substantia Nigra Induced by Paraquat Dichloride (1,1-dimethyl-4,4 bipirydinium) in Rat as a Medel of Parkinson Disease. *Indonesian J Biotech*. 10 (1): 91-98.
- Paxinos.G. 2004. *The Rat Nervous System*. Third Edition. Elsevier Akademik Press. Sydney. Australia.
- Ong, L.K., Bobrovskaya, L., Walker, F.R., Day, T.A., Dickson, P.W., and Dunkley, P.R. 2011. The Effect of Social Defeat on Tyrosine Hydroxylase Phosphorylation in the Rat Brain and Adrenal Gland. *Neurochem Res*. 36(1):27-33.
- Ray, S., Sengupta, A., and Ray. A. 2007. Effects of paraquat on anti-oxidant system in rats. *Indian Journal of Experimental Biology*. 45: 432-438.
- Reiner A. 1994. *The study of catecholaminergic perikarya and fibers in the nervous system: methodological considerations and technical limitations*. dalam *Phylogeny development of catecholamine systems in the CNS of vertebrate*, editor Smeets WJ, Reiner A, Cambridge, Cambridge University Press.
- Repetto, M., Semprine, J., and Boveris, A. 2012. Lipid Peroxidation: Chemical mechanism, Biological Implications and Analytical Determination. *InTechOpen*. 3-30.
- Uversky, V N. 2004. Neurotoxicant-induced animal models of Parkinson's disease:

understanding the role of rotenone, maneb and paraquat in neurodegeneration. *Cell tissue Res.* 318 (1): 225-41.

Schober, A. 2004. Classic toxin-induced animal models of Parkinson's disease: 6-OHDA and MPTP. *Cell Tissue Res.* 318: 215-24.

Tanner, C. M., Kamel, F. G., Ross, W., Hoppin, J. A., Goldman, S.M., Korell. M., Marras,

C., Bhudhikanok. G. S., Kasten, M., Chade, A. R., Comyns. K, Richards, M. B., Meng, C., Priestley, B., Fernandez, H.H., Cambi, F., Umbach, D.M., Blair, A., Sandler, D.P., and Langston, J.W., 2011. "Rotenone, Paraquat and Parkinson's Disease". *Environ Health Perspect* 119 (6): 866-72.