

Penile granuloma caused by liquid silicone injection

Ishandono Dachlan

Surgery Department

Faculty of Medicine, Gadjah Mada University/Dr. Sardjito Hospital, Yogyakarta

ABSTRACT

Ishandono Dachlan - *Penile granuloma caused by liquid silicone injection.*

Various alloplastic injectable implants have been developed for soft tissue augmentation without surgery. Silicone is a polymer from a family of chemically related organo-silicone compounds that may exist in any state from a fluid to a solid. Injectable liquid silicone has been used for various cosmetic treatments, mainly for soft tissue augmentation, for example lip, cheek, breast, buttock, and penile. Liquid silicone has been implicated in variety of adverse inflammatory reactions, sometimes resulting in tissue destruction.

We describe an adverse granulomatous reaction after the injection of liquid silicone for penile augmentation. Penile granuloma can occur as an adverse effect of penile enlargement with the injection of high viscosity solution, like silicone (siliconoma), paraffin (paraffinoma), vaseline or mineral oil. Penile granuloma is a rare case which needs an accurate management.

We found 30-years old man that occurs 5 weeks after non medical injection of liquid silicone. Surgical management was done with an excision of the granuloma and round incision on the upper penile, except the urethral part. There were no complications following the treatment. Histopathology examination showed the appearance of silicone-like foreign body granuloma and fibrosis of the preputium.

It is concluded that Injection liquid silicone for penile augmentation could cause adverse granulomatous. Surgical management can be done with an excision of the granuloma.

Key words: liquid silicone, penile granuloma, surgical excision.

ABSTRAK

Ishandono Dachlan - *Granuloma penis yang disebabkan oleh injeksi silikon cair.*

Berbagai macam jenis injeksi implan alloplastik telah berkembang untuk memperbesar jaringan lunak tanpa prosedur operasi. Silikon merupakan polimer dari jenis bahan kimia yang tersusun atas "*organo-silicone*" yang dapat berbentuk cair sampai padat. Injeksi silikon cair telah banyak digunakan untuk perawatan kosmetik, terutama untuk memperbesar jaringan lunak, seperti bibir, dagu, payudara, pantat, dan penis. Silikon cair dapat menimbulkan berbagai bentuk reaksi inflamasi, yang kadang-kadang menyebabkan kerusakan jaringan.

Digambarkan kasus reaksi granulomatosa lanjut setelah injeksi silikon cair yang bertujuan untuk memperbesar penis. Granuloma penis dapat terjadi setelah injeksi cairan dengan viskositas tinggi, seperti silikon cair (silikonoma), parafin (parafinoma), vaselin atau minyak mineral lainnya. Granuloma penis adalah kasus yang jarang yang memerlukan perawatan yang tepat. Dilaporkan seorang laki-laki umur 30 tahun dengan granuloma penis setelah 5 minggu penyuntikan silikon cair di luar fasilitas kesehatan. Dilakukan eksisi granuloma dan jaringan sekitarnya kecuali uretra. Tidak ditemukan komplikasi setelah operasi. Hasil histopatologi menunjukkan reaksi granuloma (silikonoma) dan fibrosis pada prepusium..

Disimpulkan bahwa injeksi silikon cair untuk memperbesar penis dapat menyebabkan reaksi granulomatosa. Pendekatan bedah dapat dilakukan dengan eksisi granuloma.

INTRODUCTION

The use of soft tissue fillers is an integral part of cosmetic dermatologic surgery. Many different types of temporary and permanent filler substances have been used in soft tissue augmentation. The materials included as implantable fillers are expanded polytetrafluoroethylene (e-PTFE), acellular dermal grafts (AlloDerm, LifeCell), vicryl mesh (Polyglactin 910), solid silicone and cartilage grafts. The other fillers are injectable substance likes human or bovine collagen, cosmoplast, Zyderm I/II, zyplast, micronized acellular dermal graft (Cymetra), paraffin, vaseline and liquid injectable silicone. Permanent filler substances approved for use in the United States is limited to extruded polytetrafluoroethylene and silastic (solid silicone) implants. Liquid silicone has been used for permanent soft tissue augmentation in the past, but the types of liquid silicone available were not approved by the FDA for medical use in the United States. The use of silicone also fell out of favor during the moratorium placed on liquid silicone-filled breast implants in the 1990s^{1,2}.

Injectable liquid silicone is chemically stable and can withstand body thermal changes and repeated steam autoclaving without changing its chemical structure. Moreover, silicone is not a favorable medium for growing microorganisms. The basic structure of silicone or "siloxane" consists of chemical chains of silicon and oxygen atoms bound to hydrocarbon groups, such as methane. The element silicon is naturally found in the human body as a component of mucopolysaccharides. The viscosity of silicone depends directly on the degree of polymerization or the chain length of the polymer. Dimethylsiloxanes are large molecules that can possess a chain length anywhere from 0 to 2,000 polymer units. The viscosity of silicone is measured in centistokes (cs). One hundred cs has the viscosity of water. The medical-grade injectable liquid silicone of the early 1960s was a polydimethylsiloxane containing 130 polymer units that had the viscosity of mineral oil at 350 cs^{2,3}.

The use of soft tissue fillers is an integral part of cosmetic dermatologic surgery. Many different types of temporary and permanent filler substances have been used in soft tissue augmentation including wide variety of materials. Silicone is a

polymer from a family of chemically related organo-silicone compounds that may exist in any state from a fluid to a solid. The compound polydimethylsiloxane is the most widely used silicone as medical implants. Silicone in elastomer (solid) form is extensively used in medicine, for example in implanted prosthetic devices and intravenous fluid tubing; silicone gel is mainly used for breast reconstruction and breast enlargement. Injectable liquid silicone has been used for various cosmetic treatments, mainly for soft tissue augmentation, for example lip, cheek, breast, buttock, and penile; and correction of facial age-related wrinkles and acne scarring⁴.

When injected intradermally and subcutaneously in animals or humans, liquid silicone develops a predictable, self-limited, nonirritant, and virtually noninflammatory foreign body reaction being seen under the microscope as dispersed vacuolization or "pseudocysts" encapsulated by collagen deposition and fibrosis. Occasionally, phagocytes and a giant cell reaction also can be seen around the droplets of silicone. Collagen deposition and fibrosis are the reasons for the tissue augmentation that occurs when silicone is injected⁵.

Although initially considered as a chemical inert material, liquid silicone has been implicated in a variety of adverse inflammatory reactions, sometimes resulting in tissue destruction. Usually they are unpredictable and occasionally uncorrectable. As a consequence, today its use must be limited to a very few and controlled investigative treatment protocols^{5,6}.

We report a case of local granulomatous reaction occurring 5 years after the subcutaneous injection of liquid silicone in the penile.

CASE REPORT

A 30 year-old man came to our Plastic Surgery Department with the main complaint of a hardening swollen penis. He told that 5 weeks before he received several subcutaneous injection of liquid silicone by a non-medical person to motivate enlarging penis measurement for sexual satisfaction. On the day when it was injected and several days later, the skin where the injection was done was red all over and there was a slight pain.

Approximate 3 days after the injection, the patient did not complain of either pain or itchy on the side of injection, and there was no sexual disorder. The patient wanted to remove the swollen part of the penis as its appearance disturbed the sight.

On physical examination, it was found the skin on the distal part of the penis was enlarged with a diameter around 5 cm when it was not erected, the consistent expression a circular solid mass was felt, looked at the color like the color of the skin around it, there were not suppressed pain, and signs of inflammation on the penis and surrounding organ (FIGURE1). According to the anamnesis and physical examination the proposed diagnosis was a granuloma on the penis caused by liquid silicone injection.

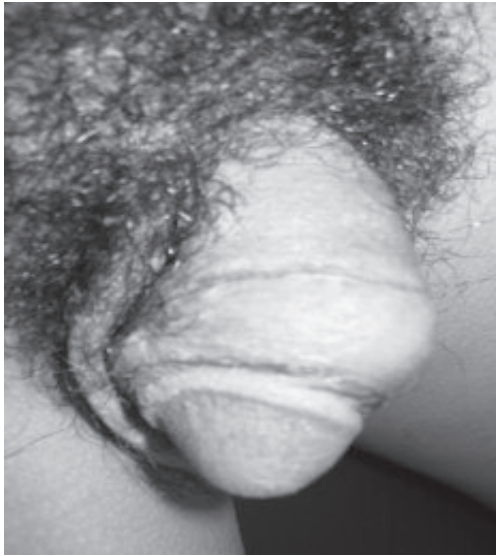

FIGURE 1: before operative condition

It was treated by radical excision granuloma with local anesthetics. The excision was done nearly encircling the tip of the penis except the urethra part. The operational wound was primary sewn (FIGURE 2). The granuloma tissue was then sent for a histopathologic examination. One week post treatment, the operation wound was good dry and no complications (FIGURE 3).

The histopathology result showed skin tissue penis with swollen granulomatous pseudotuberkel form that surrounded by empty spaces such as fat named plasma cell, numerous, large, clear vacuoles

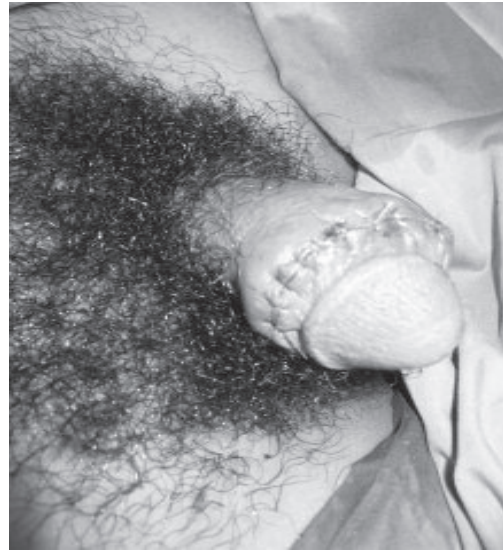

FIGURE 2: postoperation

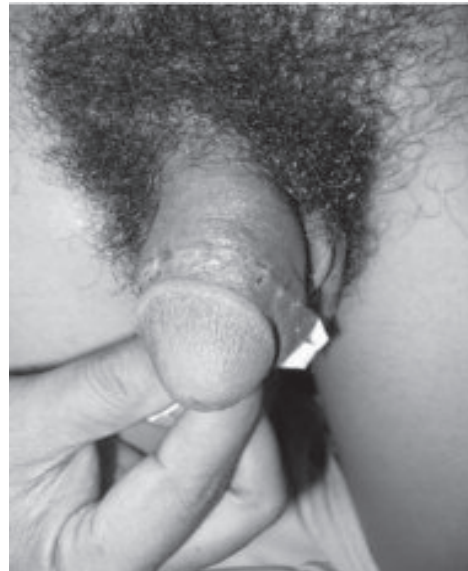

FIGURE 3: one after operation

of varying sizes, eosinophil leukocyte, and some foreign objects giant cell, mainly on its perivascular, mostly fibrosis with places with hyalinization. There was no severe signs. A conclusion was made with the presence of the image of foreign object granuloma like silicon but with spreading granulomatous lesion and fibrosis (FIGURE 4).

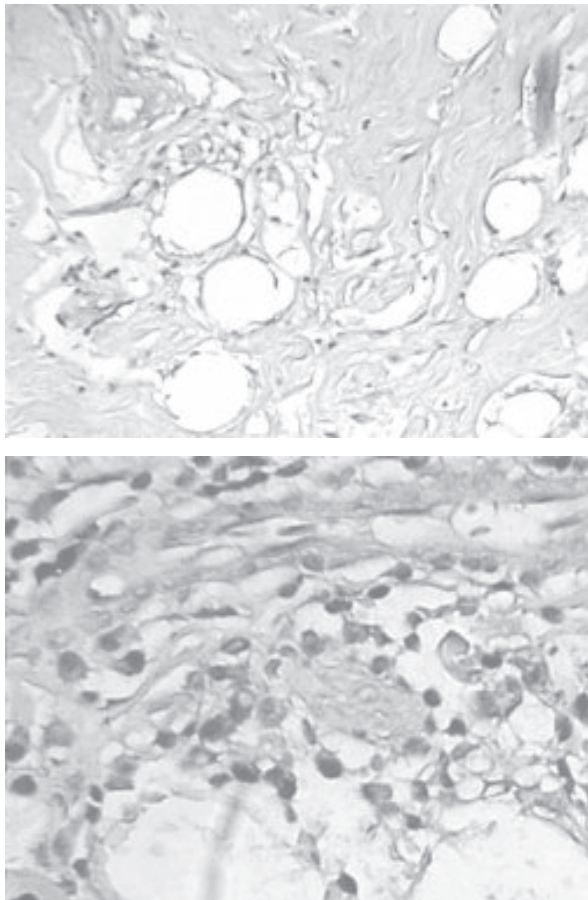


FIGURE 4. histopathology pattern

DISCUSSION

The use of soft tissue fillers is an integral part of cosmetic dermatologic surgery. Many different types of temporary and permanent filler substances have been used in soft tissue augmentation. A wide variety of materials have been used for soft tissue augmentation^{1,2}.

Penile augmentation by injecting substances such as paraffin or vaseline in the penile subcutaneous tissue is very popular in the 1900s in East Europe and Korea, mainly because of the false concept of sexual satisfaction. While the side effect of this action like pain in the penis, chronic cellulite, nodule or granuloma formation, foreign object reaction and possibly the content of substance migration was reported occurring from 3 weeks until 23 years after the injection. Lee et al reported the occurrence of 26 sclerosing lipogranuloma cases

at the average of 18.5 months after paraffin or vaseline injection. In Thailand it was also reported the side effect of penis pain in 8 cases that occurred after 2-48 months after injection with vaseline or olive oil^{7,8}.

In Indonesia, there was a scientific report concerning penis formation with content substances such as silicone, vaseline or other substances. The side effect that happened after the injection was still limited. The limited data was probably because injection action was mostly done by non medical personell. However, Lake (2002) had made a research about motivation and the production of the action of implanting penis using 'silicon' or oil to enlarge and lengthened the penis measurement around East Island⁹.

Kipping, a Nottingham chemist, coined the term *silicone* to describe polymers, which he synthesized based on the element silicon (atomic number 14), the second most abundant element in the earth's crust. Kipping referred to the materials he prepared as silicones because simple elemental analysis indicated that they may be analogues of organic ketones. Further reactions using elemental silicone resulted in a class of compounds referred to as *siloxanes*. This term is derived from "silicon," "oxygen," and "methane"^{2,10}.

Liquid silicone, pure and adulterated, has been used for soft tissue augmentation worldwide for at least 40 years, and it is estimated that at least 200,000 patients have been treated in the United States alone. The misuse of adulterated silicone and other agents purported to be silicone is still front-page news in the country, Mexico, and Asia.²⁵ The availability and legality of US Food and Drug Administration (FDA)-approved silicone oils and the likelihood that other semipermanent and permanent implants may be approved will unquestionably lead to an increased use of both liquid silicone and other implants with similar complication profiles^{2,10}.

The enactment of the FDA Modernization Act on November 21, 1997, allowed any legally marketed FDA-approved device to be prescribed or administered for any condition or disease within a doctor-patient relationship.¹⁹ Accordingly, two forms of liquid silicone that have been FDA approved for retinal tamponade, AdatoSil (Bausch

& Lomb, Claremont, CA, USA), a viscous compound of 5,000 centistokes (100 centistokes = viscosity of water), and Silikon (Alcon Labs, Fort Worth, TX, USA), a 1,000-centistoke fluid, may legally be used for soft tissue augmentation¹⁰.

Recently severe complications of implanted liquid silicone have been reported. Treatment-site reactions including pain, erythema, ecchymosis, pigmentation, tissue induration, excessive tissue elevation and migration of the material injected to distant locations causing facial deformity are common. More severe complications such as a granulomatous reaction presenting clinically as recurrent cellulitis with nodule formation, ulceration, skin induration, and local lymph enlargement have also been reported. Other severe reactions with tissue destruction and scarring as well as cases of embolism after accidental injection of silicone in the vascular system have also been described. More severe life-threatening systemic complications (acute pneumonitis, granulomatous hepatitis) have been reported following injection of large amounts of liquid silicone^{5,11,12}.

The inflammatory reactions may develop them. Granuloma is histopathology term defined as a group of hystiocytic cells with a limited number of cytoplasm accompanied by gigantic Langhans type cells. Granuloma can be associated with necrotic process, infection and foreign cells. Granuloma on a penile caused by foreign things can occur as a side effect of enlarging or enlengthening penis measurement through injecting a certain kind of liquid which has a high viscosity such as silicone, paraffin or vaseline. Thus, there is famous term for granuloma caused by silicone (siliconoma), and granuloma caused by mineral oil or plant oil (paraffinoma)^{13,14}.

Foreign objects if injected or implanted into the skin can produce a reaction of non-allergic foreign objects or focal allergic response to individual experiencing sensitivities towards those foreign objects. Some materials can trigger non allergic foreign object reaction, such as silk or nylon thread, wood, paraffin and other oil materials, silicone and powder. At histopathologic examination, the foreign object non allergic reaction showed a granulomatous response with hystiocyte penetration and gigantic cells which are often a kind of foreign object with

gigantic cells. Lymphocyte cell penetration is also found, plasma and neutrophyl cells surrounding it. Histopathologic examination on paraffinoma shows an image of 'Swiss cheese' as there are spaces in the form of ovals or circles like fat which is thought as oil substance, with fibrotic tissue in between. Granulomatous allergic reaction to foreign objects showed sarcoidosis image or tuberculoid containing epitheloid cells with or without giant cells. The substances that can cause reaction to allergic granulomatous in individual who is sensitized are zirconium, beryllium and coloring substances for tattoo^{3,7}.

In this case report the histopathology examination showed skin penis tissue with inflamed granulomatous in the form of pseudotuberkel that encircled empty spaces like fat with plasma cell powder, leukocyte eosinophyl, and some foreign object giant cell, mainly the perivascular part, and fibrosis. The result tends to show a reaction of non allergic granuloma, in the case caused by sandalwood oil injection.

The pathogenesis of granuloma caused by foreign object is not yet known for certain. It is only explained as the natural body response towards foreign objects. For granuloma caused by silicone, it is assumed that there is an activated involvement of T cells, with an increased of α tumor necrosis factor level (TNF- α), an inflammation cytokine factor that has an important role in the granuloma formation in some diseases like sarcoidosis and Chron disease. Whether the pathogenesis of granuloma occurrence caused by injecting oil is similar to the pathogenesis of silicone granuloma is not yet known for certain⁵.

Granuloma therapy can be done with a variety of modality such as the usage of systemic corticosteroid, or intralesion, antibiotic such as monocyclic, inhibitor TNF- α like infliximab and etanercept, or surgery procedure such as liposuction, laser and local resection. Operative therapy as a choice is radical excision to remove foreign objects. Another technique is by excision with mesh graft or bilateral scrotal skin flaps. In this case report a surgery was done i.e. radical excision of the granuloma. This excision was done nearly encircling the tip of the penile except the urethra part. The operation wound was primarily sewn. Postsurgery treatment a good

operation result was seen and there was no complication on the site of the surgery or on the surrounding organs^{87.8.15}.

Because of the serious aesthetic and psychologic consequence caused by the lack of response to the treatment when a granulomatous reaction occurs, we advise that silicone injection be performed solely by trained physicians using medical-grade silicone.

CONCLUSION

A granuloma penile case was reported occurring 5 weeks after injection of liquid silicone. Diagnosis was done based on the anamnesis, physical examination. A radical excision was done to the granuloma with a success. The histopathology showed the skin tissue penile with swollen granuloma.

REFERENCE

1. Tanzy MC. Plastic surgery: prosthetic and tissue Engineering Approach. Italy. 13th CIRMIB Biomaterials School Strategies and Technologies for Tissue engineering and Reparative Medicine. July 2006.
2. Duffy DM. Liquid Silicone for Soft Tissue Augmentation. *Dermatol Surg*. 2005;31:1513-39.
3. Rapaport M. Silicone Injections Revisited. *Dermatol Surg*. 2002; 28:594-96.
4. Barnett JG, Barnett CR. Treatment of Acne Scars with Liquid Silicone Injections: 30 Year Perspective. *Dermatol Surg*. 2005;31:1542-49.
5. Bigata X, Ribera M, Bielsa I, Fetzandiz C. Adverse Granulomatous Reaction After Cosmetic Dermal Silicone Injection. *Dermatol Surg*. 2001;27:198-200.
6. Shapiro PE. Noninfectious Granuloma. In: Elder D, Elenitsas S, Jaworsky C, Johnson B. eds. *Lever's Histopathology of the Skin*, 8th ed. New York. Lippincott-Raven Publishers. 1997: 317-40.
7. Hohaus K. Mineral oil granuloma of the penis. *J Eur Acad Dermatol and Venerol*. 2003;17:585-87.
8. Wiwanitkit V. Penile Injection of Foreign Bodies in Eight Thai patients. *Sex Transm Infect* 2004;80:546-49.
9. Lake P. Penile Implant and Accessories in West Timor. Kupang. Faculty of Social and Political Science, Nusa Cendana University, Bina Unsan Mandiri (YABIM) Foundation. 2005.
10. Benedetto AV, Lewis AT. Injecting 1000 Centistoke Liquid Silicone with Ease and Precision. *Dermatol Surg* 2003;29:212-15.
11. Jhastre J, Basset F, Viau F. Acute Pneumonitis after Subcutaneous Injections of Silicone in Transsexual Men. *N Engl J*. 1983; 308:764-67.
12. Maly A, Regev E, Meir K, Maly B. Tissue Reaction to Liquid Silicone Simulating Low-grade Liposarcoma Following Lip Augmentation. *J Oral Pathol Med*. 2004; 33:314-16.
13. Pasternack FR, Fox LP, Engler DE. Silicone Granuloma Treated with Etanercept. *Arch Dermatol*. 2005;14 :13-15.
14. Lee T, Paraffinoma of the Penis. *Yonsei Med J*. 1994; 35(3):344-48.
15. Grippaudo FR. Ultrasound-assisted Liposuction for the Removal of Siliconoma. *Scand J Plast Reconstr & Hand Surg*. 2004; 38: 21-26.