

The acceleration of garlic (*Allium sativum* L) ethanolic extract on gingival wound healing process in Wistar rats

Indra Bramanti^{1*}, Ngatidjan², Setyo Purwono²

¹Department of Dentistry for Children, Faculty of Dentistry, Department of Pharmacology and Therapy, Faculty of Medicine, Universitas Gadjah Mada Yogyakarta, Indonesia

ABSTRACT

Garlic (*Allium sativum* L) is a medicinal plant traditionally used to relieve pain. Garlic's active constituents, allicin and triacremone, have been proven to have antibacterial and antiinflammatory activity. The aim of this study was to investigate the effect of garlic ethanolic extract gel in gingival wound healing process of rats. Thirty male Wistar rats aged 10 weeks with body weight 200-250 g were subjected in this study. Rats were divided randomly into five groups with six rats in each group. Group I as negative control was given sodium carboxymethyl cellulose (Na CMC) base gel. Group II as positive control was given Benzylamine[®] gel and Group IV-V were given garlic ethanolic extract gel at dose of 20, 40 and 80%, respectively. Each group was subdivided into two sub groups of three rats according to the decapitation period which were 5th (D-5) and 7th (D-7) day after the garlic extract gel application. Excisional wounds using punch biopsy, 2.5 mm in diameter, were created at the mandibular labial gingiva between right and left incisor teeth of the rats. The garlic extract gel of each preparation dose was then applied on the wound three times a day, starting at 0 day until 7th day. The decapitation was conducted on the D-5 and D-7. Histological slides of wounded tissue were prepared. Epithelial thickness, new blood vessel, and number of fibroblast were examined. The results showed that the epithelial thickness of garlic ethanolic extract gel groups was significantly higher than control group ($p < 0.05$), especially after 5th day application. However, the number of new blood vessels and the amount of fibroblast of those groups were not significantly higher than control group ($p > 0.05$). In conclusion, topical application of garlic ethanolic extract gel accelerates the gingival wound healing process in rats by increasing epithelial thickness.

ABSTRAK

Bawang putih (*Allium sativum* L) merupakan tanaman obat yang secara tradisional digunakan untuk meredakan nyeri. Kandungan aktif bawang putih yaitu alisin dan triakremonon terbukti mempunyai aktivitas antibakteri dan antiinflamasi. Penelitian ini bertujuan untuk mengkaji efek gel ekstrak etanol bawang putih pada proses penyembuhan luka gingiva tikus. Tiga puluh tikus jantan Wistar berumur 10 minggu dengan berat badan 200-250 g digunakan dalam penelitian ini. Tikus dibagi menjadi lima kelompok secara acak dengan enam ekor setiap kelompok. Kelompok I sebagai kontrol diberi natrium karboksilmetil selulosa (Na CMC). Kelompok II sebagai kontrol positif diberi gel Benzylamine[®]. Kelompok III-IV diberi gel ekstrak etanol bawang putih berturut-turut pada dosis 20, 40 dan 80%. Masing kelompok selanjutnya dibagi dalam dua sub kelompok masing-masing tiga ekor tikus menurut waktu dekapitasi yaitu hari ke 5 (H-5) dan 7 (H-7) setelah pemberian gel ekstrak bawang putih. Luka eksisi dengan *punch biopsy* berdiameter 2,5 mm dibuat pada gingiva labial rahang bawah, di antara gigi incisivus kanan dan kiri tikus. Gel ekstrak bawang putih untuk setiap dosis sediaan dioleskan pada luka tiga kali sehari dari hari ke 0 sampai ketujuh. Dekapitasi dilakukan pada H-5 dan H-7. Preparat histologi jaringan yang luka dibuat. Ketebalan epitelium, pembuluh darah baru, jumlah fibroblas diukur dan dihitung. Hasil penelitian menunjukkan bahwa ketebalan epitelium kelompok yang diberi gel ekstrak etanol

* corresponding author: bramantikg@gmail.com

bawang putih lebih tinggi dibandingkan kelompok kontrol ($p < 0,05$) khususnya setelah hari ke 5 pemberian. Namun demikian, jumlah pembuluh darah baru dan fibroblas kelompok tersebut tidak lebih tinggi secara nyata dibandingkan kelompok kontrol ($p > 0,05$). Dapat disimpulkan bahwa pemberian ekstrak etanol bawang putih topikal mempercepat proses penyembuhan luka gingiva tikus dengan meningkatkan ketebalan epitelium.

Keywords: garlic ethanolic extract - gingival wound healing - epithelium thickness - fibroblast - angiogenesis

INTRODUCTION

Oral health cannot be separated from the general health. Oral cavity disorder or illness will cause dysfunction of mastication, phonetics, and aesthetics. Oral cavity disorder can be caused by physical, chemical or mechanical trauma that can lead to injury.^{1,2} Injured tissue will undergo wound healing as a natural process of the body to replace damaged tissue into a healthy one. Wound healing process consists of three overlap and dynamic phases, which are inflammatory phase, proliferative phase, and maturation phase.³

Inflammatory phase is characterized by vascular reaction and recruitment of inflammatory cellular components to the site of injury, such as polymorphonuclear leukocytes (PMN) cells.^{4,5} Polymorphonuclear leukocytes are predominant cells in the first three days after injury and usually lasts for 5 days.⁶ Another acute phase inflammatory marker is the increase expression of cyclooxygenase-2 (COX-2).⁷ Proliferative phase occurs after signs of inflammation subsides. It is characterized by epithelialization, angiogenesis and proliferation of fibroblast.⁴ Transformation of fibroblasts becomes myofibroblast occurs in the transformation phase, which result in contraction of the wound.⁸

Several drugs are available on the market for wound healing process acceleration in the oral cavity with various pharmacological activities. Chlorhexidine (Peridex[®]) is used as an antiseptic,⁹ hyaluronic acid (Alloclair[®]) as

natural wound healing,¹⁰ and free protein extract of calf blood (Solcoseryl[®]) as analgesic and antiinflammatory agent.¹¹ Moreover, corticosteroids and non steroid anti-inflammatory drugs (NSAIDs) are also often used on oral cavity wound healing.¹² However, drugs for oral cavity wound healing are relatively expensive and some of them cause serious side effects. Therefore, the availability of drugs that is not expensive and has minimal side effects for oral cavity wound healing is needed.

Traditional medicines have been promoted by Indonesian government as alternative medicine for wound healing.¹³ Garlic (*Allium sativum* L) is a medicinal plant that traditionally used in Greeks as pain relief.¹⁴ It also has been used to treat toothache and struma.¹⁵ The garlic extract in combination with honey significantly accelerates wound healing process and the rates of wounds sterility in rats.¹⁶ An active constituent of garlic namely allicin has been isolated and proven to have antibacterial and anti-inflammatory activities,¹⁷ while triacremone, another active constituent, has anti-inflammatory and arthritis effects by inhibition of NF- κ B.¹⁸ This study was conducted to investigate the effect of garlic extract on the gingival wound healing of rats and its possible mechanism.

MATERIALS AND METHODS

Animals

This was a pure experimental with post test only control group design using 30 male Wistar rats aged 10 weeks with body weight 200-250g

obtained from Department of Pharmacology and Therapy, Faculty of Medicine, Universitas Gadjah Mada, Yogyakarta. Rats were divided randomly into five groups with six rats in each group. Group I as negative control was given sodium carboxymethyl cellulose (Na CMC) 4% w/w base gel. Group II as positive control was given Benzdamine[®] gel and Group IV-V were given garlic ethanolic extract gel with dose of 20, 40 and 80%, respectively. Each group was subdivided into two sub groups of three rats according to the decapitation period which were 5th (D-5) and 7th (D-7) day after wounded. Therefore there were 10 sub groups in this study according to treatment and decapitation period. This study was started after obtaining an approval from the Medical and Health Research Ethics Committee, Faculty of Medicine, Universitas Gadjah Mada, Yogyakarta.

Experimental procedures

Extract preparation

Garlic ethanolic extract was prepared in Integrated Research and Testing Laboratory, Universitas Gadjah Mada. The garlic was purchased in a traditional market in Tawangmangu, Central Java and identified by comparison with reference specimens in Department of Pharmacy Biology, Faculty of Pharmacy, Universitas Gadjah Mada. The garlic was washed, stored at 4 °C for 24 hours and blended with ethanol. Extracts were then prepared by maceration of the garlic juice with 70% ethanol solvent for 24 hours. The macerate was separated by filtration and concentrated by a rotary evaporator to obtain an ethanolic extract of garlic.

Garlic extract gel preparation

Garlic extract gel was prepared in Department of Pharmaceutical Technology, Faculty of Pharmacy, Universitas Gadjah Mada.

Methylparaben 0.8 g and propylparaben 0.4 were dissolved 40 mL of aquadest using heat to about 70 °C with stirring and cooled. The solution was then added in a porcelain mortar containing 4 g of Na CMC and mixed with stirring. Aquadest was then added up to 100 mL and stirred until base gel gained. The garlic extract at each preparation dose (20, 40 and 80%) was then added to the gel base and stirred to obtain the homogenous garlic gel extract preparation. The gel was stored in a refrigerator until used.

Allicin and alliin identification and total flavonoid quantification

Active constituents namely allicin and alliin of garlic extract and gel were identified using thin layer chromatography (TLC) method in Integrated Research and Testing Laboratory, Universitas Gadjah Mada. The extract or gel was reconstituted by the addition of ethanol (1 mg/mL). Approximately 15 µL of the solution was then spotted near the bottom of silica gel GF254-precoated TLC plate. The TLC plate was placed in a shallow pool of a mobile phase in a developing chamber. The mobile phase constituted n-butanol : n-propanolol : acetic acid : aquadest (3:1:1:1). The allicin was identified visually by sodium nitroprusside reagent continued by sodium cyanide reagent while alliin was identified by ninhydrin reagent. The R_f value of the two constituents was then measured.

The concentration of total flavonoids in garlic extract and gel was estimated by colorimetric method using aluminium trichloride (AlCl₃) and sodium hydroxide (NaOH).¹⁹ Fifty mg of garlic extract or gel was mixed with 0.3 mL of a 50 g/L solution of sodium nitrite (NaNO₂). After five minutes of incubation at ambient temperature, 0.6 mL of a 100 g/L solution of aluminium trichloride (AlCl₃·6H₂O). After five minutes of incubation and addition

of 2 mL of a 1 mol/L solution NaOH, the volume was brought to 10.0 mL aquadest and the absorbance was measured at λ 510 nm. The same procedure was repeated for the standard solution of quercetin (6.25 to 200 μ g/mL) and the calibration curve was made. Based on the measured absorbance, the concentration of flavonoids was calculated (g/100 mL) on the calibration line. The concentration of total flavonoids in garlic extract or gel was expressed in terms of quercetin equivalent.

Animal wound creation and garlic extract gel administration

Animal wound creation and garlic extract gel administration were conducted in the Department of Pharmacology and Therapy, Faculty of Medicine, Universitas Gadjah Mada. The rats were anaesthetized by intramuscular 100 mg/kg ketamine HCl before the experiment. The mandibular labial gingiva skin was cleansed with 70% alcohol before wound creation. Excisional wounds using punch biopsy, 2.5 mm in diameter, were created at the mandibular labial gingiva between right and left incisor teeth of the rats. The garlic extract gel of each preparation dose was then applied on the wound three times a day, starting at 0 day until 7th day. The decapitation was conducted on the 5th and 7th day after the garlic extract gel administration for each group. The wounded gingival tissue samples were taken, washed in physiological saline (sodium chloride 0.9%) sterile solution, immersed into 10% buffered formalin and stored at 4 °C not more 24 hours for histological examination.

Histological examination

Histological examination was conducted in the Department of Anatomic Pathology, Faculty of Medicine, Universitas Gadjah Mada. One night after the store, samples were removed from

the store and placed in fresh fixative. Fixed tissue samples were processed routinely by paraffin embedding technique. Sections of 5 μ m were obtained and stained with hematoxylin-eosin. The thickness of epithelium, the number of new blood vessels (angiogenesis) and the number of fibroblasts of the preparations were evaluated using a light microscope by the same pathologist who was blinded to the treatment groups.

Statistical analysis

The SPSS program was used for statistical analysis. The data were expressed as mean \pm SD. Statistical comparisons between the groups were tested with the two way analysis of variance (ANOVA) continued by t-test post ANOVA or least significant difference (LSD) test. Values of $p < 0.05$ were considered statistically significant.

RESULTS

Tissue repair was studied in the different groups by comparing inflammatory and proliferative processes and tissue reorganization. For this purpose, samples were collected from the wound area two, six, ten and 14 days after experimentally induced injury. Temporal differences in tissue repair were observed between the different treatments.

Alliin and alliin identification and total flavonoids quantification

Chemical identification revealed that the garlic ethanolic extract and gel contain alliin as well as alliin (FIGURE 1). The presence of alliin was identified as brown spots after visualization with sodium nitroprusside and sodium cyanide reagents on TLC results while alliin was identified as orange red spots with ninhydrin reagent. In addition, total flavonoids amounted to 0.73, 0.68 and 3.67% in 20% garlic

extract gel, 20% garlic extract and 100% garlic extract respectively.

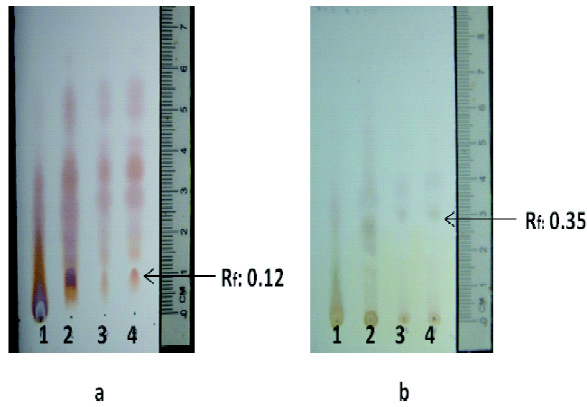


FIGURE 1. TLC chromatograms of garlic ethanolic extract and gel (a) after visualization with sodium nitroprusside and sodium cyanide reagents and (b) after visualization with ninhydrin reagent. Stationary phase is silica gel GF254 and mobile phase was n-buthanol : n-proprano : aquadest : acetic acid (3:1:1:1 v/v). The chromatogram 1, 2, 3 and 4 are garlic ethanolic extract 100%, 80%, 20% and garlic ethanolic extract gel 20%, respectively. The R_f value of alliin is 0.12 (FIGURE a) and allicin is 0.35 (FIGURE b).

Epithelial thickness

Epithelial thickness of gingival wound tissues on Wistar rats was measured using a micrometer from histological images in 100x magnification that captured and digitized using photomicroscope. The epithelial thickness was measured 10 time for each image from the basal layer to the deepest rete peg to the outer epithelial layer on D-5 and D-7. FIGURE 2 shows the epithelial thickness of gingival wound tissues on D-5 on negative control where not complete epithelialization was observed (FIGURE 2a) and 20% garlic ethanolic extract group where reepithelialization was observed (FIGURE 2b).

Epithelial thickness of gingival wound tissues on Wistar rats in each group after D-5 and D-7 garlic ethanolic extract gel application is presented in TABLE 1. The epithelial thickness of gingival wound tissues was influenced by the duration and the dose of garlic ethanolic extract gel application. The epithelial thickness of gingival wound tissues on D-5 was higher than D-7 on both control group and garlic ethanolic extract gel groups ($p < 0.05$). On D-5, the epithelial thickness of gingival wound

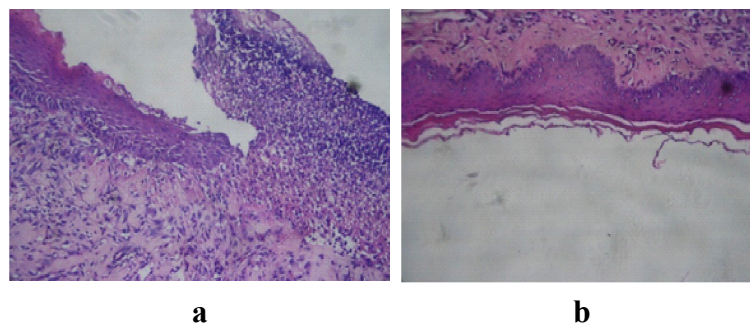


FIGURE 2. Photomicrographs of epithelial thickness of gingival wound on D-5 with magnification 100x on (a) negative control and (b) 20% garlic ethanolic extract gel application

tissues in all of garlic ethanolic extract gel groups and positive control were significantly higher than negative control ($p < 0.05$). However, on D-7 significantly different in epithelial thickness of gingival wound tissues compared to negative

control was observed only in 40 and 80% garlic ethanolic extract gel groups and positive control ($p < 0.05$). No significantly different was observed between 20% garlic ethanolic extract gel group and negative control ($p > 0.05$).

TABLE 1. Epithelial thickness (mean \pm SD μ m) of gingival wound on Wistar rats in each group after D-5 and D-7 garlic ethanolic extract gel application

| Groups | Decapitation period | |
|---|---------------------|--------------------|
| | Day 5 | Day 7 |
| I. Negative control (Na CMC) | 77.30 \pm 13.02 | 52.90 \pm 13.65 |
| II. 20% garlic ethanolic extract gel | 112.20 \pm 13.06 | 67.43 \pm 28.15 |
| III. 40% garlic ethanolic extract gel | 122.10 \pm 13.43 | 90.33 \pm 15.19 |
| IV. 80% garlic ethanolic extract gel | 129.70 \pm 14.48 | 108.13 \pm 19.56 |
| V. Positive control (Benzylamine [®]) | 137.47 \pm 14.74 | 98.47 \pm 24.32 |

Number of new blood vessels

The formation of new blood vessels in gingival wound tissues was observed using a light microscope in 450x magnification. The observation was performed on 10 microscope fields of view in each histological preparation of slides. FIGURE 3 shows the number of new

blood vessels of gingival wound on D-5 on negative control (FIGURE 3a) and 20% garlic ethanolic extract (FIGURE 3b). The new blood vessels were characterized with cavities surrounded by endothelial cells either containing erythrocytes or not. Moreover, smooth muscle cells did not appear.

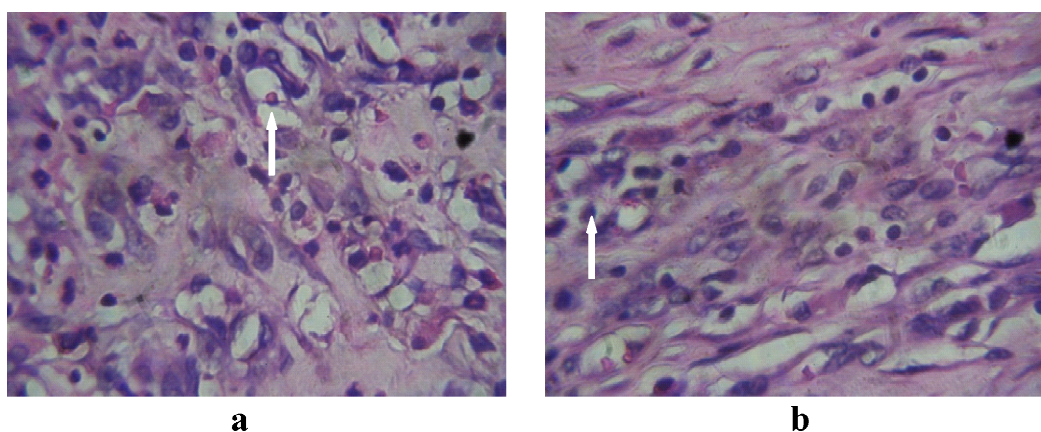


FIGURE 3. Photomicrographs of new blood vessels of gingival wound on D-5 with magnification 100x on (a) negative control and (b) 20% garlic ethanolic extract gel application

The number of new blood vessels in gingival wound tissues of Wistar rats in each group after D-5 and D-7 garlic ethanolic extract gel application is presented in TABLE 2. The number of new blood vessels in gingival wound tissues on D-5 tended to be higher than on D-7 on both control group and garlic ethanolic extract gel groups. However, it was

not significantly different ($p>0.05$), except on 20% garlic ethanolic gel group ($p<0.05$). No significantly different in number of new blood vessels was observed between the garlic ethanolic extract and positive control groups compared to negative control group both on D-5 and D-7 ($p>0.05$).

TABLE 2. Number new blood vessels (mean \pm SD μ m) in gingival wound of Wistar rats on each group after D-5 and D-7 garlic ethanolic extract gel application

| Groups | Decapitation period | |
|--|---------------------|-------------------|
| | Day 5 | Day 7 |
| I. Negative control (Na CMC) | 65.33 \pm 31.72 | 54.00 \pm 26.21 |
| II. 20% garlic ethanolic extract gel | 71.67 \pm 16.04 | 23.67 \pm 8.62 |
| III. 40% garlic ethanolic extract gel | 66.00 \pm 33.45 | 60.00 \pm 17.09 |
| IV. 80% garlic ethanolic extract gel | 58.33 \pm 14.46 | 43.00 \pm 3.00 |
| V. Positive control (Benzzydamine [®]) | 63.67 \pm 23.03 | 46.67 \pm 13.65 |

Number of fibroblasts

The number of fibroblasts in gingival wound tissues was also observed using a light microscope in 450x magnification that conducted on 10 microscope fields of view in each histological preparation of slides. FIGURE 4 shows the number of fibroblasts in

gingival wound on D-5 on negative control (FIGURE 4a) and 20% garlic ethanolic extract (FIGURE 4b). The fibroblasts were characterized by the existence of pink cells with blue nuclei. In young granulation tissue, the fibroblast can be observed as thin ovoid cells with large ovoid nuclei.

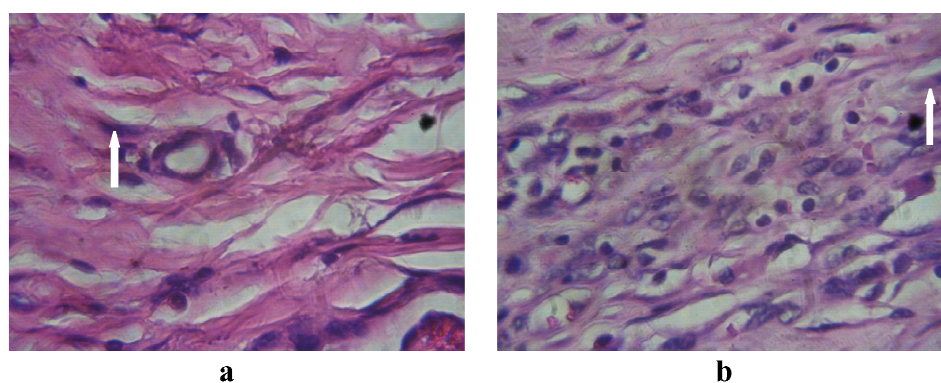


FIGURE 4. Photomicrograps of fibroblasts of gingival wound on D-5 with magnification 100x on (a) negative control and (b) 20% garlic ethanolic extract gel application

The number of fibroblasts in gingival wound tissues of Wistar rats in each group after D-5 and D-7 garlic ethanolic extract gel application is presented in TABLE 3. The number of fibroblasts in gingival wound tissues of negative control, 20% garlic ethanolic extract group and positive control on D-7 were higher than those on D-5 ($p < 0.05$). Although, the number of fibroblasts on 40 and 80% garlic

ethanolic extract groups on D-7 tended to be higher compared to those on D-5, it was not significantly different ($p > 0.05$). Furthermore, no significant difference in number of fibroblasts was observed between the garlic ethanolic extract and positive control groups compared to negative control group both on D-5 and D-7 ($p > 0.05$).

TABLE 3. Number fibroblasts (mean \pm SD μ m) in gingival wound of Wistar rats on each group after D-5 and D-7 garlic ethanolic extract gel application

| Groups | Decapitation period | |
|---|---------------------|--------------------|
| | Day 5 | Day 7 |
| I. Negative control (Na CMC) | 77.67 \pm 18.50 | 147.33 \pm 30.27 |
| II. 20% garlic ethanolic extract gel | 76.33 \pm 18.01 | 125.33 \pm 6.03 |
| III. 40% garlic ethanolic extract gel | 82.00 \pm 29.05 | 148.67 \pm 71.60 |
| IV. 80% garlic ethanolic extract gel | 117.00 \pm 23.07 | 184.67 \pm 71.82 |
| V. Positive control (Benzydamine [®]) | 99.67 \pm 27.54 | 169.33 \pm 22.85 |

DISCUSSION

Wound healing process is divided into three phases namely inflammatory phase, proliferative phase and remodeling phase.²⁰ The inflammatory phase is characterized by infiltration of inflammatory cells in the injured tissue whereas the proliferative phase is characterized by angiogenesis, fibroplasia and re-epithelization.²¹ In the remodeling phase, collagen is remodeled and realigned along tension lines and cells that are no longer needed are removed by apoptosis.²²

Many medicinal plants have been found to have wound healing activities. Some plant extracts have been formulated for clinical use in wound management and have proved safe and efficacious.²³ Garlic is one of the most ancient vegetables and its medicinal used are dated back more 5,000 years.²⁴ In Greek, garlic has been

used traditionally as pain relief.¹⁴ It also has been used to treat toothache and struma.¹⁵ Garlic possesses some pharmacological activities, such as antimicrobial,²⁵ antioxidant, anticancer activities,²⁶ and anti-inflammatory.²⁷

The effect of garlic on wound healing process may be contributed of some active constituents of garlic such as allicin, flavonoids and triacremone as anti-inflammatory agent.^{17,18,28} This anti-inflammatory effect of garlic stimulates the proliferative phase of wound healing that characterized by the occurrence of re-epithelization and the formation of new blood vessels and fibroblast.²¹

This study found that garlic accelerated the re-epithelization in wound healing process as indicated with the higher of the epithelial thickness of gingival wound tissues of Wistar rats after application of the garlic ethanolic

extract gel compared to negative control. The activity of garlic in acceleration of wound healing was similar to Benzzydamine® as positive control. However, the effect of garlic in the formation of new blood vessels and fibroblasts can not be proven in this study. The number of new blood vessels as well as the number of fibroblasts after the garlic ethanolic extract gel application were not significantly different compared to negative control.

CONCLUSION

It can be concluded that the topical application of garlic ethanolic extract gel can accelerate the gingival wound healing process in rats as indicated by the increase of epithelium thickness in the wound tissues.

ACKNOWLEDGEMENTS

I would like to express my deepest gratitude to Prof. Dr. Mustofa, Apt., MKes., and Prof. Dr. Mae Sri Hartati, MSi., Apt. for their suggestions during the research.

REFERENCES

1. Chrismawaty E. Peran struktur mukosa rongga mulut dalam mekanisme blokade fisik terhadap iritan. MIKGI 2006; 5: 244.
2. Mackay D and Miller AL. Nutritional support for wound healing. Alternat Med Rev 2003; 8(4): 359-77.
3. Torre J and Sholar A. Wound healing: chronic wounds. eMedicine.com [serial online] 2006 [cited Jun 2011]. Available from: www.medicine woundhealing/ chronicwound.html.
4. Kumar V, Abbas AK, Fausto N. Pathologic basic of disease. Philadelphia: Elsevier Saunders, 2005.
5. Baratawidjaya KG. Imunologi dasar, Edisi 7. Jakarta: Fakultas Kedokteran Universitas Indonesia, 2006.
6. Gilletzer R and Goebeler M. Chemokines in cutaneous wound healing. J Leukocyte Biol 2001; 69: 513-21.
7. Schror K and Meyer-Kirchrath J. Cyclooxygenase-2 inhibition and side-effects of non-steroidal anti-inflammatory drugs in the gastrointestinal tract. Curr Med Chem 2000;7 (11): 1121-9.
8. Phillips LG. Wound healing. In: Beauchamp RD, Evers BM, Mattox KL editors. Sabiston textbook of surgery: the biological basis of modern surgical practice. 16th ed. Philadelphia: WB Soundrs Inc., 2001.
9. Shahab A, Haghghati F, Baeeri M, Jamalifar H, Abdollahi M. A clinical, microbiological and immunological comparison between subgingival irrigation with Dentol and chlorhexidine in advanced periodontitis. Arch Med Sci 2011; 7(1):154-60.
10. López-Jornet P, Camacho-Alonso F, Martinez-Canovas A. Clinical evaluation of polyvinylpyrrolidone sodium hyaluronate gel and 0.2% chlorhexidine gel for pain after oral mucosa biopsy: a preliminary study. J Oral Maxillofac Surg 2010; 68(9):2159-63.
11. Ochi M, Wang PL, Ohura K, Takashima S, Kagami H, Hirose Y, et al. Solcoseryl, a tissue respiration stimulating agent, significantly enhances the effect of capacitively coupled electric field on the promotion of bone formation around dental implants. Clin Oral Implants Res 2003;14(3):294-302.
12. Osunde OD, Adebola RA, Omeje UK. Management of inflammatory complications in third molar surgery: a review of the literature. Afr Health Sci 2011; 11(3): 530-7.
13. Tripathi KD. Essentials of medical pharmacology. 5th ed. New Delhi: Jaypee Brothers, 2003.
14. Roser D. Bawang putih untuk kesehatan. Jakarta: Bumi Aksara, 1991.
15. Agoes A, Halimi ES, Djafar ZR, Kamaluddin MT, Bakti AR, Muhammad S, Joedijaningsih, Arsjad KM. Studi pengobatan dan jenis ramuan tanaman obat di Propinsi Sumatra Selatan. MKS 2000; 32 (1): 4-10.
16. Sidik AA, Mahmood AA, Salmah I. Acceleration of wound healing by aqueous extract of *Allium sativum* in combination with honey on cutaneous wound healing in rats. Int J Mol Sci 2006; 2(2): 231-5.
17. Santoso BH. Bawang putih. Yogyakarta: Kanisius, 1998.
18. Ban OJ, Oh, JH, Kim TM, Kim DJ, Jeong HS, Han SB, Hong JT. Anti-inflammatory and arthritic

- effects of thiacremonone, a novel sulfur-compound isolated from garlic via inhibition of NF- κ B. *Arthritis Res Ther* 2009; 11(5): R145. Doi: 10.1186/ar2819.
19. Dewanto V, Wu X, Adom KK, Liu RH. Thermal processing enhances the nutritional value of tomatoes by increasing total antioxidant activity. *J Agri Food Chem* 2002; 50(10): 3010–4.
 20. Mitchell V, Cotran RS. Acute and chronic inflammation. In: Robbins SL, Kumar V editors. *Robbins basic pathology*. 7th ed. Philadelphia: WB Saunders Company, 2003.
 21. Romo III T. Wound healing, skin. eMedicine.com [serial online] 2012 [cited 21012 August 12th]. Available on: <http://emedicine.medscape.com/article/884594-overview>.
 22. Greenhalgh DG. The role of apoptosis in wound healing. *Int J Biochem Cell Biol* 1998; 30 (9): 1019–30.
 23. Ogwang PE, Nyafuono J, Agwaya M, Omujal F, Tumusiime HR, Kyakulaga AH. Preclinical efficacy and safety of herbal formulation for management of wounds. *Afr Health Sci* 2011; 11(3):524-9.
 24. Gamboa-Leon MR, Aranda-Gonzalez I, Mut-Martin M, Garcia-Miss MR, Dumonteil E. *In vivo* and *in vitro* control of *Leishmania mexicana* due to garlic-induced NO production. *Scand J Immunol* 2007; 66(5):508–14.
 25. Ramoutar RR, Brumaghim JL. Antioxidant and anticancer properties and mechanisms of inorganic selenium, oxo-sulfur, and oxo-selenium compounds. *Cell Biochem Biophys* 2010; 58(1): 1–23.
 26. Nagini S. Cancer chemoprevention by garlic and its organosulfur compounds-panacea or promise? *Anticancer Agents Med Chem* 2008; 8(3):313–21.
 27. Lang A, Lahav M, Sakhnini E, Barshack I, Fidler HH, Avidan B, *et al.* Allicin inhibits spontaneous and TNF-alpha induced secretion of proinflammatory cytokines and chemokines from intestinal epithelial cells. *Clin Nutr* 2004; 23(5):1199-208.
 28. Amagase H. Clarifying the real bioactive constituents of garlic. *J Nutr* 2006; 136(3 suppl): 716S–25S.