



## Evaluation of varicocelectomy operative therapy for infertile couples at the UGM Academic Hospital

\*Wikan Kurniawan, Sulis Ernawati, Linggar Dwi Cahyo, and Achmad Yudha Nur Hendra

Rumah Sakit Akademik Universitas Gadjah Mada

\*Corresponding author: [wikankurniawan@ugm.ac.id](mailto:wikankurniawan@ugm.ac.id)

Submitted: July 2023

Reviewed: July 2023

Publish: September 2023

### Abstract

**Background:** Infertility is a condition of the male or female reproductive system characterized by failure to achieve pregnancy after 12 months or more of having regular sexual intercourse without contraception. Since 2013, Rumah Sakit Akademik UGM (RSA UGM) has providing varicocele therapy to infertile individuals. The Ivanissevich varicocelectomy procedure is used for varicocele therapy. This study intends to examine the management of varicocele patients at RSA UGM. **Materials and method:** This research is a retrospective study by opening medical records and interviews. The study population was all patients who underwent varicocelectomy surgery between 2013 and 2021. Data is presented in the form of graphs. **Results:** The distribution of varicocele lateralization showed that out of 35 respondents, 23 respondents (66%) had one side varicoceles and 12 respondents (34%) both sides varicoceles. The distribution based on successful pregnancy shows that out of 35 respondents, 10 respondent couples (29%) have already gotten pregnant, 25 respondents (71%) haven't gotten pregnant. The distribution of varicocele lateralization in respondents who have children shows that 70% of respondents are one side and 30% of respondents are both sides. Complications of discomfort revealed that 88% of research participants had no complaints of postoperative pain, whereas 11% occasionally suffered pain following varicocele surgery. **Conclusion:** Varicocele that is one side is more common. Patients with one side varicocele who have surgery are more likely to become parents than those with both sides varicocele. At RSA UGM, the varicocelectomy success rate is comparable to the worldwide success rate.

**Keywords:** *Varicocele, success rate, one side, both sides*

## 1. Introduction

Infertility is a condition of the male or female reproductive system characterized by failure to achieve pregnancy after 12 months or more of having regular sexual intercourse without contraception(1). A couple with primary infertility has never conceived, while a person with secondary infertility has conceived once or more times but is having trouble conceiving again(2). About 40–50% of all cases of infertility are "male factor" disorders. Up to 2% of all infertile males will have sperm parameters that aren't ideal. Low sperm concentration, slow sperm movement, or aberrant morphology could all be contributing factors(3). Male infertility can be brought on by both reversible and irreversible conditions. Age, drugs, surgical history, exposure to chemicals in the environment, genetic issues, and systemic disorders are all variables that may have an impact on either partner(4). One of the most prevalent reasons of male infertility is varicocele(5). An inflated pampiniform plexus, a system of tiny veins in charge of draining venous blood from the testis and the deep tissues of the hemiscrotum, is referred to as a varicocele. This plexus is connected to the ipsilateral gonadal vein, which empties into the inferior vena cava on the right and the renal vein on the left(6). Varicoceles affect 15% to 20% of adult male population, and 40% of infertile men have it(7).

There is currently no agreed-upon "gold standard" for the care of varicocele. The three most common varicocelelectomy techniques are laparoscopic, open retroperitoneal ligation (Palomo), and open inguinal ligation (Ivanissevich)(8). Subinguinal, high inguinal, microsurgical-inguinal, and subinguinal, laparoscopic surgery are a few other surgical therapy possibilities. The radiological methods of treating varicoceles include sclerosing and embolization, both antegrade and retrograde(9). Operative therapy is not always required, according to additional research. Regardless of the grade or age of the varicocele, two-thirds of Tanner V boys with an uncorrected varicocele and normal testicular volume reach normal TMC. Without surgery, 47% of patients with initial "poor" sperm analysis will progress to normal status regardless of Tanner V advancement. In

particular in the subset of individuals who have chronically poor TMC on serial Sperm Analysis, careful selection of patients to avoid over-treating must be matched with close active observation to prevent under-treating (10).

Since 2013, Rumah Sakit Akademik UGM (RSA UGM) has offered services to patients with varicocele who are infertile. The Ivanissevich varicocelelectomy procedure is used to treat varicoceles. This study intends to assess RSA UGM's approach to treating varicocele patients. The following factors were assessed: varicocele lateralization distribution, pregnancy success rate, varicocele lateralization distribution in respondents who successfully had children, and postoperative pain issues.

## 2. Materials and Methods

### Research Methods

Retrospective methodology is being used in this study. Searching through the medical files of patients who underwent surgery at the RSA UGM between 2013 and 2021. In-depth interviews are used to supplement deficient medical record data. The period of data gathering was from June to October 2022. The Faculty of Medicine, Public Health, and Nursing, Gadjah Mada University (Ref. No.: KE/FK/0808/EC/2022, dated 24 June 2022) Medical and Health Research Ethics Committee (MHRC) clearance was required before the study could be carried out.

### Data Analysis

The gathered data is entered into Microsoft Excel, where it is then evaluated by aggregating the data and shown as tables or graphs.

## 3. Results

Figure 1. shows according to the distribution of varicocele lateralization, 12 (34%) and 23 (66%) of the 35 respondents had both side varicoceles, respectively.

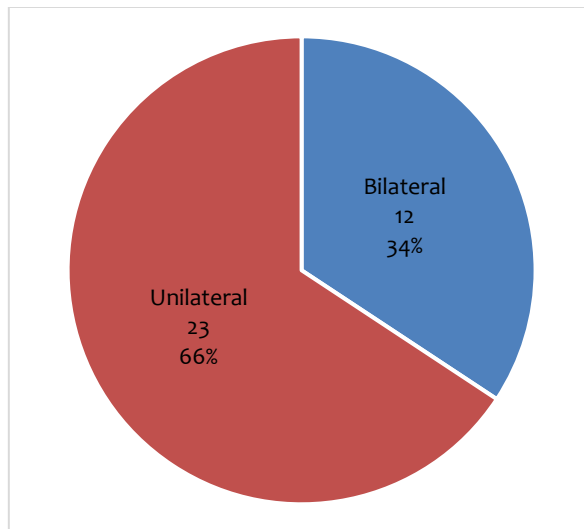


Figure 1. Varicocele lateralization

Figure 2 shows the distribution of respondents depending on pregnancy success. Out of 35

respondents, 10 respondent couples (29%) had conceived, whereas 25 respondents (71%) had not.

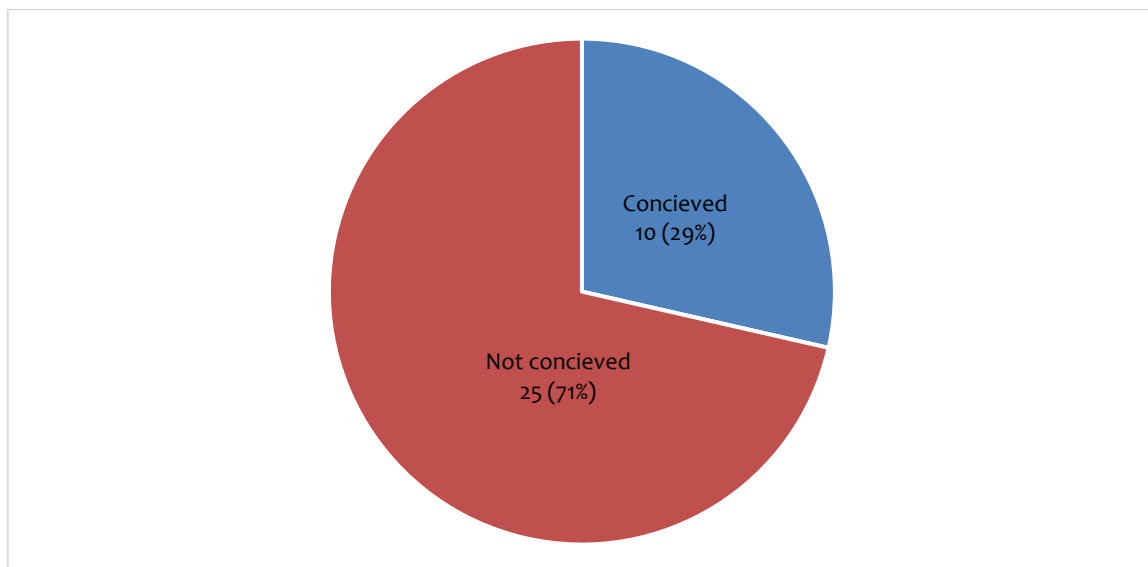


Figure 2. Respondent distribution according on conception success

Figure 3 shows the distribution of respondents depending on pregnancy success. Out of 10 respondent couples that succeeded pregnancy after varicocele surgery at the age of 28 there

were 2 respondents and the other respondents were at the ages of 30, 31, 34, 38, 41, 42, 46 and 47 years.

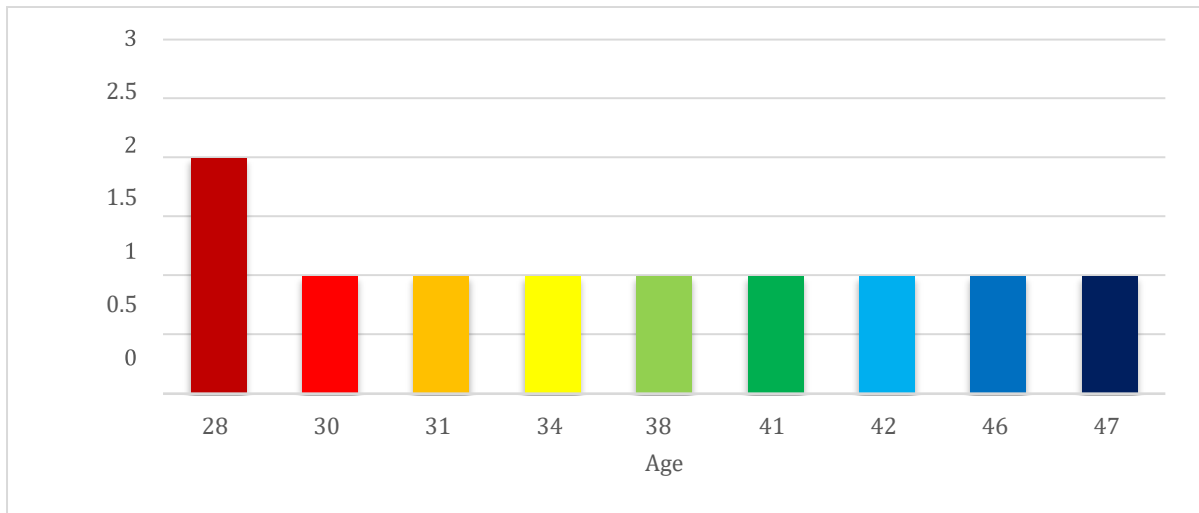


Figure 3. Age of respondents that pregnancy success

Figure 4 depicts the distribution of varicocele lateralization among respondents with children. Of the 10 respondents to the research who had

children following varicocele surgery, 7 (70%) had one side lateralization and 3 (30%) had both side lateralization.

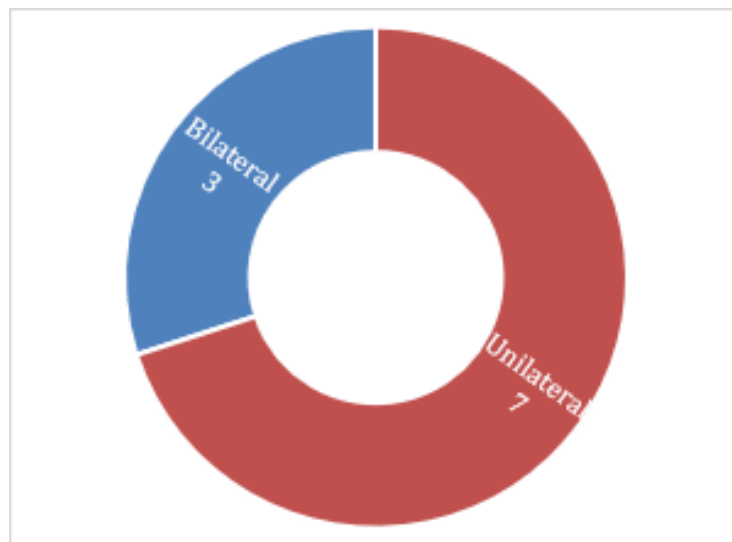


Figure 4. Varicocele lateralization distribution in respondents having children

Figure 5 illustrates pain problems. Of the 35 participants in the postoperative varicocele study, 4 (11%) occasionally reported varicocele

pain, while 31 (88%) reported no complaints of postoperative pain.

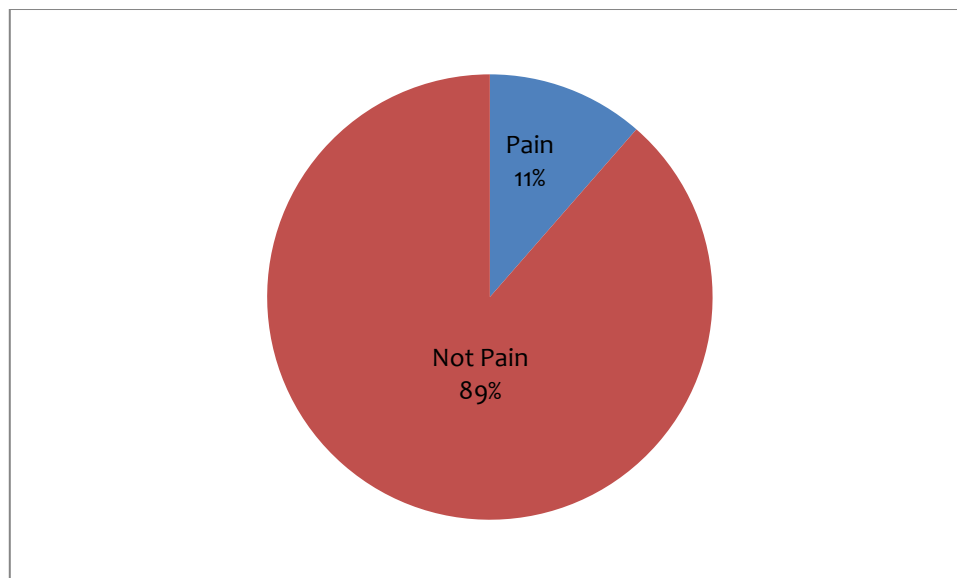


Figure 5. Pain problem

#### 4. Discussion

One of Indonesia's teaching hospitals is Rumah Sakit Akademik (RSA) UGM. Varicocele surgery is one of the urological therapies offered to couples who are infertile due to varicocele. Research samples have been collected since this facility opened its doors in 2013. Due to the low number of patient visits at the time, 35 responses made up the research samples. There were also research participants who objected to being questioned.

This study was conducted more than 3 months had passed since the surgery. The goal is for the outcomes to be as good as possible. Practically speaking, determining how quickly semen characteristics improve following varicocele treatment is crucial, especially in older couples. The full spermatogenic cycle lasts 64 days in humans. Sperm parameters improved within the first three months following varicocele surgery, but did not continue to improve after that, according to studies examining the time interval between varicolectomy and improvement of semen parameters. The ASRM Practice Committee has so noted that an improvement in semen parameters is typically noticed after 3 to 6 months. These results highlight the necessity to proceed with additional techniques to varicolectomy as soon as possible and are helpful for developing therapy options for candidates(11).

One-sided varicoceles were present in 23 responders (66%), the majority of the sample. In the left testicle, varicoceles were far more frequent (80% to 90%). There is a 30% to 40% probability that a left varicocele will be both side. Three theories about underlying anatomical factors, specifically:

1. When the left internal spermatic vein is compressed between the superior mesenteric artery and the aorta, the "Nutcracker" effect takes place. The spermatic veins are obstructed and compressed as a result of this entrapment.
2. Anti-reflux valve malfunction where the internal spermatic vein connects to the left renal vein. The testicular veins experience reflux and retrograde flow as a result of this failure.
3. An angle where the left internal spermatic vein and left renal vein meet(12).

Further research is required on a body of literature that highlights the pathophysiological alterations that lead to both side varicocele. For instance, it is not known with certainty whether valves exist or not. Wishahi meticulously dissected 70 fresh cadavers after injecting glue into their gonadal veins. In addition to the lack of venous valves, it has been observed that all gonadal veins have branch veins that emerge from the L-4 region and anastomose with collaterals from the renal capsule. The ipsilateral colonic vein is collateralized with in an additional 77% of cases. In 55% of cases, vessels that communicated at the L3 level with vessels on the opposite side underwent analysis(13).

A total of 35 respondents took part in the study; 25 respondents (71%) were not pregnant, whereas 10 pairs of respondents (29%) had. Pregnancy rates for open surgery range from 33.57 to 37.6% (14). Surgery at RSA UGM results in a pregnancy rate that is a little lower than in Europe. This can be as a result of the few patients and facility and the need of technology advancements.

The best varicocele surgery keeps testicular function intact while thoroughly removing the varicocele with a low risk of hydrocele formation,

nearby nerve injury, or other potential problems(15). However, a method that is actually perfect has not yet been discovered. The RSA UGM has been using the Ivanissevich procedure ever since the varicocelectomy service began. The reason for choosing this procedure is that it has a higher success rate. Sperm parameters are improved with varicocelectomy. Sperm normal motility and morphology were similar using the Palomo, Ivanissevich, and laparoscopic procedures. Ivanissevich, however, was more successful in raising sperm concentration(8). It is hoped that the chance of conceiving will be higher with a higher sperm concentration.

Studies conducted in the lab and in clinic have shown that varicocele negatively affects spermatogenesis. At the age of 18 to 20 years old, testicular function is typically normal but gradually declines depending on the length of the varicocele. Ipsilateral testicular atrophy caused by clinical varicocele may improve with varicocele repair(16).

Patients with a diagnosis of one side varicocele make about 70% of respondents who can have children. This is quite likely to happen since a high, lengthy, and both side grade will cause more damage from varicocele than the opposite will. Of course, the ipsilateral testis is the only one affected by a one side varicocele. Routine semen values did not significantly differ between infertile men with one side and both side varicoceles. Patients with both side varicoceles, however, had much greater FSH levels and smaller testes, which can be a symptom of a compensated spermatogenic function (17). Other research yields different findings. Clinically discernible varicoceles and altered hormonal rhythms may or may not be related. Although hormonal alterations are addressed in some studies, nothing is known about how they are used in clinical settings. The hormone testosterone is the subject of the most research. Leydig cell dysfunction is known to be caused by varicoceles in a variety of ways, and the longer the varicocele is present, the more damaged the cells become. Inhibition of enzymes involved in sex steroid biosynthesis results in a decrease in intratesticular production and testosterone conversion as a result of an increase in scrotal temperature, ROS generation, and hypoxia. As a result of a reversible pathogenic process, numerous investigations have found that varicocelectomy greatly boosts Leydig cell activity and testosterone production (18). The size and consistency of the softer testicles were predominantly associated with high-grade and both side varicoceles, and these findings were

particularly prominent in older subjects. When assessing patients for androgen deficiency syndrome, it should also be considered that individuals with both side varicoceles and grade 3 or greater frequently have lower testosterone levels(13). It is probable that both side varicoceles have a lower conception rate than one side varicoceles, based on the aforementioned studies.

One of the risks of surgery is pain, 11% of responders to this research reported experiencing pain. Following Ivanissevich's operation, there were  $2.71 \pm 1.87\%$  more pain problems (8). In comparison to the literature, the postoperative pain rate in RSA UGM is greater. By creating better methods and infrastructure, this needs to be addressed. It's also important to take into account the limited sample size.

In a varicocele, there are primarily two types of pain: discomfort from the varicocele itself and pain from the varicocelectomy procedure itself. It is unclear what causes the scrotal pain that comes with varicocele. Theoretical explanations include the dilated venous complex compressing adjacent nerve fibers, elevated scrotal temperature, oxidative damage to the testicular parenchyma, and tissue ischemia brought on by venous stasis(19).

Nerve injury that causes acute neuropathic pain is one of the major risk factors for the development of acute to chronic pain. Chronic postoperative pain is much more common than is usually thought and the estimated incidence of severe chronic pain of greater than 5/10 intensity occurs in 2% to 10% of patients after surgery. In addition to nerve injury as a risk factor, other risk factors include pre-existing preoperative pain, preoperative anxiety, catastrophe, as well as genetic predisposition. Postoperative factors were again severe acute postoperative pain and psycho-social risk factors similar to those in the preoperative setting (20). The ilioinguinal nerve and the genital ramus of the genitofemoral nerve will almost certainly be damaged during the varicocelectomy procedure. This is due to the fact that the nerve structure is close to the pampiniform venous plexus structure.

Preemptive analgesia, a method of pain management that eliminates peripheral and central sensitization discomfort before noxious stimulation, has been shown to be useful in reducing postoperative pain(21). Regarding the administration of preemptive analgesia, there are divergent views. Analgesic medicine is given before a surgical damage or tissue harm occurs

and is referred to as preemptive analgesia. However, the benefits of initial vs post-incident analgesia are ambiguously supported by a number of randomized clinical trials. The use of preemptive analgesia does not consistently result in therapeutic benefits following surgery according to the current broad consensus(22). Until this article was written, RSA UGM had not used preemptive analgesia. This study shows the importance of preemptive analgesia, so that preemptive analgesia will be given in the future.

## 5. Conclusion

One side varicocele patient make up the majority of the infertile varicocele patients seen at the UGM Academic Hospital. Patients at the academic hospital at UGM have a pregnancy rate that is very similar to the success rate for pregnancies throughout Europe. It is imperative to improve surgical facilities and procedures since pain problems following varicocele surgery are higher than European standards.

## 6. Acknowledgements

This research was funded by Gadjah Mada University staff research grants, RKAT RSA UGM funds.

## 7. Conflict of interests

The researcher declares that there is no conflict of interest in the research, authorization and/or publication of this article.

## References

1. WHO. <https://www.who.int/news-room/fact-sheets/detail/infertility> (accessed on 12/12/2020). available online :<https://www.who.int/news-room/fact-sheets/detail/infertility>: WHO; 2022. p. 1 Infertility. Available from: <https://www.who.int/news-room/fact-sheets/detail/infertility>
2. Leaver RB. of Causes and Treatment Options. *British Journal of Nursing*. 2016;25(18):35–41.
3. Kumar N, Singh A. Trends of male factor infertility, an important cause of infertility: A review of literature. *Journal of Human Reproductive Sciences*. 2015;8(4):191–6.
4. SW L, LE S, TL SS, Khan MA. Male Infertility - StatPearls - NCBI Bookshelf source 1. Treasure Island (FL): StatPearls Publishing LLC; 2021. p. 1–70.
5. Kantartzi PD, Goulis CD, Goulis GD, Papadimas I. Male infertility and varicocele: Myths and reality. *Hippokratia*. 2007;11(3):99–104.
6. Lundy SD, Sabanegh ES. Varicocele management for infertility and pain: A systematic review. *Arab Journal of Urology*. 2018;16(1):157–70.
7. Stephen W. Leslie, Hussain S, Larry E S. Varicocele - StatPearls - NCBI Bookshelf. NCBI. treasure island: StatPearls Publishing LLC.; 2020. p. 1–15.
8. Hosseini K, Nejatifar M, Kabir A. Comparison of the efficacy and safety of palomo, Ivanissevich and laparoscopic varicoelectomy in Iranian infertile men with palpable varicocele. *International Journal of Fertility and Sterility*. 2018;12(1):81–7.
9. Cannarella R, Calogero AE, Condorelli RA, Giaccone F, Aversa A, La Vignera S. Management and treatment of varicocele in children and adolescents: An endocrinologic perspective. *Journal of Clinical Medicine*. 2019;8(9):1–11.
10. Chu D, Zderic SA, R SA, Srinivasan AK, Tasian GE, Weiss DA, et al. The natural history of semen parameters in untreated asymptomatic adolescent varicocele patients: A retrospective cohort study. *J Pediatric Urol*. 2017;13(February 2017):1–12.
11. Chiba K, Fujisawa M. Clinical Outcomes of Varicocele Repair in Infertile Men: A Review. *The World Journal of Men's Health*. 2016;34(2):101.
12. Leslie S, Sajjad H, Siref L. Varicocele - StatPearls. National Library of Medicine. 2022;1–13.
13. Besiroglu H, Otunctemur A, Dursun M, Ozbek E. The prevalence and severity of varicocele in adult population over the age of forty years old: a cross-sectional study. *Aging Male*. 2019;22(3):207–13.
14. Kupis Ł, Dobroński PA, Radziszewski P. Varicocele as a source of male infertility – current treatment techniques. *Cent European J Urol*. 2015;68:365–70.

15. Raheem O. Surgical management of adolescent varicocele: Systematic review of the world literature. *Urology Annals*. 2013;5(3):133–9.
16. Bertolotto M, Freeman S, Richenberg J, Belfield J, Dogra V, Huang DY, et al. Ultrasound evaluation of varicoceles: systematic literature review and rationale of the ESUR-SPIWG Guidelines and Recommendations. *Journal of Ultrasound*. 2020;23(4):487–507.
17. DM N, Meng M, Sheth M, Cohen M, Turek P. Are Bilateral Varicoceles More Harmful to Spermatogenesis than Unilateral Varicoceles in Infertile Men? - *Fertility and Sterility*. *Fertility and Sterility*. 2000;1.
18. Bellastella G, Carotenuto R, Caiazza F, Longo M, Cirillo P, Scappaticcio L, et al. Varicocele: An Endocrinological Perspective. *Frontiers in Reproductive Health*. 2022;4(April).
19. Owen RC, McCormick BJ, Figler BD, Coward RM. A review of varicocele repair for pain. *Translational Andrology and Urology*. 2017;6(Suppl 1):S20–9.
20. Pogatzki-Zahn EM, Segelcke D, Schug SA. Postoperative pain—from mechanisms to treatment. *Pain Reports*. 2017;2(2).
21. Chen J qing, Wu Z, Wen L you, Miao J zhong, Hu Y ming, Xue R. Preoperative and postoperative analgesic techniques in the treatment of patients undergoing transabdominal hysterectomy: A preliminary randomized trial. *BMC Anesthesiology*. 2015;15(1):1–7.
22. Rosero EB, Joshi GP. Preemptive, preventive, multimodal analgesia: What do they really mean? *Plastic and Reconstructive Surgery*. 2014;134(4):85S-93S.