

## Potency of Sunkist Orange (*Citrus sinensis* L. Osbeck) against Kidney Histology of White Wistar Rats Induced by Gentamicin

Masdalena Nasution<sup>1</sup>, Chrismis Novalinda Ginting<sup>2\*</sup>, Edy Fachrial<sup>3</sup>, I Nyoman Ehrich Lister<sup>4</sup>

<sup>1</sup> Master in Biomedical Sciences Faculty of Medicine, Universitas Prima Indonesia, Medan, North Sumatera

<sup>2</sup> Department of Physiology Faculty of Medicine, Universitas Prima Indonesia, Medan, North Sumatera

<sup>3</sup> Laboratory of Biomolecular Faculty of Medicine, Universitas Prima Indonesia, Medan, North Sumatera

<sup>4</sup> Faculty of Medicine, Universitas Prima Indonesia, Medan, North Sumatera

### ABSTRACT

About 1.7%-58% of all cases of acute kidney failure are caused by gentamicin nephrotoxicity and consequently increasing urea and creatinine levels in the blood which are indications of damage to function. Oranges contain secondary metabolites such as flavonoids, alkaloids, coumarin, limonoid, keratinoid and essential oil that have pharmacological activities such as antioxidants, anti-inflammatory, anti-cancer, and also nephroprotector. The purpose of this study is to evaluate the nephroprotective activity of *Citrus sinensis* peel ethanol extract (EEKJS) on rats induced by gentamicin. Rats were induced using gentamicin at a dose of 80 mg/kgBW intraperitoneally on the 7<sup>th</sup> day after induced at a dose of 50 mg/kgBW, 100 mg/kgBW, and 200 mg/kgBW for 7 days. The results obtained from the ethanol extract of *Citrus sinensis* peel gave nephroprotective with the lowest serum creatinine and urea levels at a dose of 200 mg/kgBW which was  $0.4 \pm 0.02$  mg/dl and  $43.33 \pm 2.51$  mg/dl and difference significantly ( $p < 0.05$ ) with a positive control group which was only induced by gentamicin and histopathological results showed significant cell damage in the positive control group that was only induced by gentamicin, and in the 50 mg/kgBW dose group, 100 mg/kgBW, 200 mg/kgBW had cell repair after gentamicin induction. *Citrus sinensis* are highly recommended to be a food supplement for kidney protection.

**Keywords:** Nephroprotective; *Citrus sinensis* peel; Gentamicin; Creatinine; Urea

### INTRODUCTION

Gentamicin is an antibiotic class of aminoglycoside which useful to treat infection caused by bacteria especially Gram-negative bacteria (Gelaw *et al.*, 2014). Around 1.7% to 58% patients who received aminoglycoside therapy had been reported that have nephrotoxicity (Tahir *et al.*, 2016). The acute (reduction of renal function or urine output suddenly) or chronic usually diagnosed from elevated of the serum markers like urea and creatinine levels significantly (Udupa *et al.*, 2019). Gentamicin caused the nephrotoxicity through tubular epithelial cell necrosis and alteration in transport water and solutes (Randjelovic *et al.*, 2017). The mechanism of nephrotoxicity induced by gentamicin increasing numerous proinflammatory cytokines including tumor necrosis factor-alpha (TNF- $\alpha$ ) and intercellular adhesion molecule-1 (ICAM-1) (Yarijani *et al.*, 2015). Citrus fruits are the most consumed fruit by many people. People well-known the *Citrus Sinensis* L. Osbeck) as navel orange, Sunkist orange, or sweet orange (Pandey *et al.*, 2016). Citrus fruits have been consumed widely because of their phytochemical nutrients have an

antioxidant property to prevent the chronic and degenerative diseases such as cancer and atherosclerosis (Etebu *et al.*, 2014). *Citrus sinensis* is rich of secondary metabolite sources that have been identified in fruits, peel, leaves, juice, and roots include flavonoids, steroids, hydroxyamides, alkanes, fatty acids, coumarins, peptides, carbohydrates, carbamates, alkylamines, carotenoids, volatile compounds, and nutritional elements such as potassium, magnesium, calcium, and sodium (Favela-Hernandez *et al.*, 2016). *Citrus sinensis* showed good radical-scavenging activity and nephroprotective effects against gentamicin therapy induced renal damage (Dosoky *et al.*, 2018).

### METHODOLOGY

#### Materials

The experimental animals used in this study were the white male rats (*Rattus novvegicus*) Wistar strain, male sex, aged 2-3 months with 170-gram body weight of approximately 10% ethanol extract of *Citrus sinensis* peel, ethanol 96%, Bouchardat reactor, Dragendorff, Mayer, ferro (III) chloride, Molisch, lead (II) acetate, sulfuric acid, hydrochloric acid, methanol, chloroform-isopropanol, Liebermann Burchard, n-hexane,

\*Corresponding author : ChrismisNovalinda Ginting  
Email : yysunpri@gmail.com

toluene, chloroform, aquades, gentamicin injection 40mg/ml, and CMC.

## Methods

### Preparation of Ethanol Extract of *Citrus sinensis* peel

Oranges were taken from the Medan District area, PancurBatu. *Citrus sinensis* peel was determined at Herbarium Medanese, MIPA faculty, University of North Sumatera, Medan. *Citrus sinensis* peel was sorted wet, washed under running water, drained in a drying cabinet until it was dry, sorting dry, then weighing it, and stored in a tightly closed plastic container. Total of 700 g simplicial powder is put into a glass container, added 96% ethanol as much as 5 L, cover and leave for 5 days, protected from the light while once stirring, strain, squeeze, wash the pulp with liquid using a filter to taste up to 2 L. Transfer it to a closed vessel, leave it in a cool place, protect it from light for 2 days then filter it. The results obtained were concentrated with a rotary evaporator until most of the solvents evaporated and followed by the evaporation process until the thick extract was obtained.

### Preparation of Reagents and Test Materials

Making suspension of *Citrus sinensis* peel ethanol extract in 3 dose variations will be used, that is 50 mg/kgBW dose, 100 mg/kgBW dose, 200 mg/kgBW dose. Then, make the formalin buffer solution, the formalin buffer solution was made by adding 4 gram  $\text{NaH}_2\text{PO}_4$  and 6.5 gram of  $\text{Na}_2\text{HPO}_4$  into 40% formalin, then being prepared with aquadest to 1000 ml.

### Phytochemical Screening of *Citrus sinensis* Simplicia

Phytochemical screening of simplicial powder of *Citrus sinensis* peel includes the examination of flavonoid, alkaloid, saponin, tannin, glycoside, and steroid/triterpenoid compounds.

#### Examination of flavonoids

Added 10 grams of sample to the 100 ml of hot water, boiled for 5 minutes and filtrate in hot condition, take 5 ml of filtrate and put in a test tube, added 0.1 gram of magnesium powder and 1 ml of concentrated hydrochloric acid and 2 ml of amyl alcohol into the 5 ml of filtrate, shake and let it separated. Flavonoids were positive if red, yellow or orange occurs on the amyl alcohol layer.

#### Examination of alkaloid

Simplicia powder was weighed as much as 0.5 gram then added 1 ml of 2 N hydrochloric acid and 9 ml of distilled water, heated over a water

bath for 2 minutes, let it cooled and then filtered it. The filtrate obtained was used for the alkaloid examination 3 test tubes were taken, then 0.5 ml of the filtrate was added. In the first test tube, added 2 drops of Mayer reagent. In the second tube, added 2 drops of Bouchardat reagent. In the third tube, added 2 drops of positive Dragendorff Alkaloid reagent, if there is sediment or turbidity at least two of the three experiments above.

#### Examination of saponin

Simplicia powder was weighed as much as 0.5 grams and put into a test tube, added 10 ml of hot water, let it cooled and then shaken vigorously for 10 seconds. If foam as high as 1-10 cm is formed which is stable not less than 10 minutes and does not disappear by adding 1 drop of 2 N hydrochloric acid shown that presence of saponins.

#### Examination of tannin

Simplicia powder was weighed as much as 1 gram, boiled for 2 minutes in 100 ml of distilled water then cooled and filtered. In the filtrate, 1-2 drops of 1% ferro (III) reagent was added. If there is a blackish-blue or blackish green indicates the tannin was present.

#### Examination of glycosides

Simplicia powder was weighed as much as 2 gram, then filtered with 20 ml of 95% ethanol mixed with water (7:2) and 10 ml of 2 N hydrochloric acids, refluxed for 2 hours, cooled and filtered. Add 25 ml of distilled water and 25 ml of lead (II) acetate 0.4 M into the 20 ml of filtrate, shake it and left for 5 minutes then filtered. The filtrate was carried out with 20 ml mixture of isopropanol and chloroform (2:2), carried out repeatedly twice. Water juice was collected and evaporated at temperature no more than 500°C. The rest was dissolved in 2 ml of methanol. the remaining solution was used for the following experiment: 0.1 ml of the experimental solution was put in a test tube and evaporated over a water bath. The remaining 2 ml of water is added and 5 drops of Molisch reagent. Then slowly add 2 ml of concentrated sulfuric acid through the tube wall, forming a purple ring at the second boundary of the liquid shows a glycoside.

#### Examination of steroid/triterpenoid

Macerated 1 gram of simplicia powder with 20 ml ether for 2 hours, filtered, then the filtrate was evaporated in the evaporating dish. In the remaining 20 drops of anhydride acetic acid and 1 drop of concentrated sulfuric acid (Lieberman Bouchard reagent) was dropped when reacting to the sample. If a blue or green-blue was formed,

it was indicated steroids. While the red, pink or purple color indicated the triterpenoid was present.

**Nephroprotective Effect Test om Creatinine and Urea Levels**

The nephroprotective effect test procedure refers to the modification of Bhusan (Bhusan *et al.*, 2012).

**Preparation of experimental animals**

All male white mice were acclimatized with their environment for 7 days and given normal treatment. Each cage is given chaff, eat and drinks regularly.

**Treatment of experimental animals**

Experimental animals are grouped into 6 groups. Each consists of 5 rats.

Group I: normal treatment only ate and drank for 7 days (Normal); Group II: given gentamicin 80 mg/kgBW intraperitoneally on the first day until day 7 (Positive control); Group III: Na CMC 1% bb orally (Solvent control); Group IV: given ethanol extract of *Citrus sinensis* peel suspension dose 50 mg/kgBW orally; Group V: given ethanol extract of *Citrus sinensis* peel suspension dose 100 mg/kgBW orally; Group VI: given ethanol extract of *Citrus sinensis* peel suspension dose 200 mg/kgBW orally Then, after an hour after the extract was given, give 80 mg/kgBW gentamicin to the rat intraperitoneal except in group 1. The treatment was carried out for 7 days, then the rats have fasted for 10 hours after the last treatment. On the 8<sup>th</sup> day, all experimental animals were sacrificed using dislocation to the neck, then the blood samples of mice were immediately taken to measure creatinine and urea levels and rats were taken for histological research.

**Histological Examination of Kidney Tissue with Coloration**

**Preparation of paraffin block**

The kidney samples soaked in 10% formalin solution were then dehydrated with multilevel alcohol (70%, 80%, 95%). In each process carried out for 30 minutes to an hour, then wash them with xylol solution. Samples soaked in a mixture of xylol and liquid paraffin at a temperature 60-70°C, with the ratio of xylol: paraffin (3:1, 1:1, 1:3) for 2 hours and then print them and let it freeze. Cut the paraffin blocks using a microtome with slices of 5-7 µm. Then colored with hematoxylin and eosin staining.

Table I. Phytochemical Screening Result of *Citrus sinensis*

No	Secondary Metabolite	Result
1.	Flavonoid	+
2.	Tannin	+
3.	Saponin	+
4.	Steroid	-
5.	Terpenoid	+
6.	Glycoside	+
7.	Alkaloid	+

**Data Analysis**

The results of the research data were analyzed using the SPSS version 17.0 program. Data were analyzed using the Sapiro-Wilk method to determine normality and homogeneity testing. Then proceed using the One-Way ANOVA method to determine the average difference between groups. If there is a difference, it is continued by using the Tukey HSD Post Hoc test to see the real differences between treatments.

**RESULT AND DISCUSSION**

The results of phytochemical screening showed the presence of flavonoids, tannins, saponins, terpenoids, glycosides, and alkaloids. The results of the phytochemical screening of *Citrus sinensis* can be seen in Table I.

**Serum Creatinine Levels**

In this study, serum creatinine was examined from the mice's blood. A serum creatinine examination was carried out in the Medan area health laboratory. The serum creatinine results obtained can be seen in Table II below.

Based on the result, known that the average serum creatinine value for the negative group is still in the range of the normal value was 0.4 mg/dl. The positive control group had an average serum creatinine was 1.04 mg/dl. The treatment group of 50 mg/kgbw *Citrus sinensis* peel extract had a serum creatinine value was 0.48 mg/dl. The treatment group of 100 mg/kgbw *Citrus sinensis* peel extract had a serum creatinine value was 0.44 mg/dl. The treatment group of 200 mg/kgbw *Citrus sinensis* peel extract had a serum creatinine value was 0.4 mg/dl.

Based on Table II, known that the average serum creatinine in the largest treatment group was 0.48 mg/dl by giving the 50 mg/kgbw of *Citrus sinensis* peel extract. The mean serum creatinine in

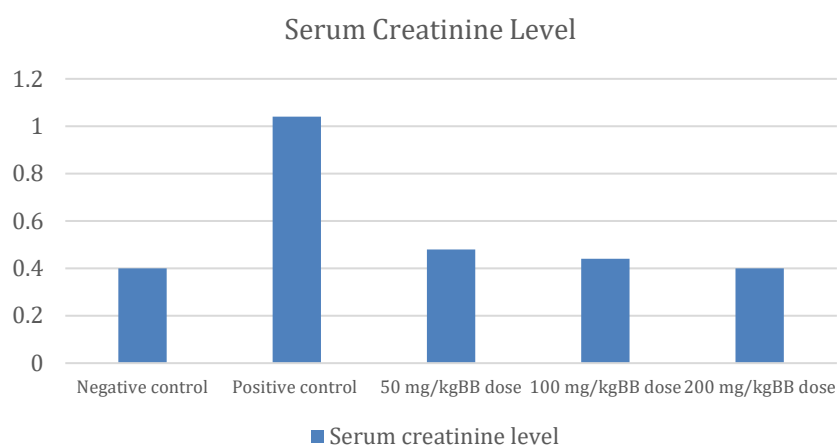


Figure 1. Serum Creatinine Level

Table II. Serum Creatinine Level

No.	Group	Serum Creatinine Level (mg/dl) Mean ± SD
1.	Normal	0.4 ± 0.02
2.	Negative control	1.04 ± 0.05
3.	Treatment group ( <i>Citrus sinensis</i> peel extract 50 mg/kgbw)	0.48 ± 0.02
4.	Treatment group ( <i>Citrus sinensis</i> peel extract 100 mg/kgbw)	0.44 ± 0.03
5.	Treatment group ( <i>Citrus sinensis</i> peel extract 200 mg/kgbw)	0.4 ± 0.02

Table III. Serum Urea Level

No	Group	Serum Urea Level (mg/dl) Mean ± SD
1.	Normal	40 ± 2
2.	Negative control	97.3 ± 4.04
3.	Treatment group ( <i>Citrus sinensis</i> peel extract 50 mg/kgbw)	46.66 ± 3.05
4.	Treatment group ( <i>Citrus sinensis</i> peel extract 100 mg/kgbw)	54.33 ± 1.52
5.	Treatment group ( <i>Citrus sinensis</i> peel extract 200 mg/kgbw)	43.33 ± 2.51

the smallest group was 0.4 mg/dl by giving the 200 mg/kgbw of *Citrus sinensis* peel extract. In addition, it can be seen that there is a decrease in serum creatinine levels if the dose of *Citrus sinensis* peel extract was increased. The average bar chart of serum creatinine measurements in male rats can be seen in the Figure 1.

### Serum Urea level

In this study, serum urea was examined from the mice blood. Examination of serum urea was carried out in the Medan area health laboratory. The serum urea results obtained can be seen in Table III.

Base on the table, known that the average serum urea value for the negative group is still in the range of the normal value was 40 mg/dl. The positive control group had an average serum urea was 97.3 mg/dl. The treatment group of 50

mg/kgbw *Citrus sinensis* peel extract had a serum urea value was 46.66 mg/dl. The treatment group of 100 mg/kgbw *Citrus sinensis* peel extract had a serum urea value was 54.33 mg/dl. The treatment group of 200 mg/kgbw *Citrus sinensis* peel extract had a serum urea value was 43.33 mg/dl.

Based on table 3, known that the average serum urea in the largest treatment group was 54.33 mg/dl by giving the 100 mg/kgbw of *Citrus sinensis* peel extract. The mean serum urea in the smallest group was 43.33 mg/dl by giving the 200 mg/kgbw of *Citrus sinensis* peel extract. In addition, it can be seen that there is a decrease in serum urea levels if the dose of *Citrus sinensis* peel extract was increased. The average bar chart of serum urea measurements in male rats can be seen in the figure 2.

Based on the statistical test result, the serum creatinine level and serum urea of the normal

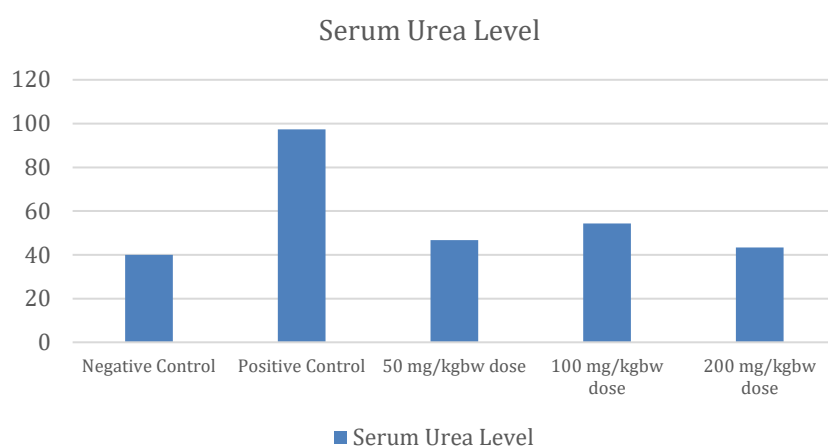


Figure 2. Serum Urea Level

Table IV. Histopathology Results of Kidney Organ

Groups	Glomerular atrophy	Changes in tubular lumane	Necrosis
Normal	-	-	-
Negative control	++	++	++
Treatment group ( <i>Citrus sinensis</i> peel extract 50 mg/kgbw)	-	-	+
Treatment group ( <i>Citrus sinensis</i> peel extract 100 mg/kgbw)	-	-	-
Treatment group ( <i>Citrus sinensis</i> peel extract 200 mg/kgbw)	-	-	-

Note: (-): Normal; (+): Mild, (++) : Moderate

group had a significant difference ( $p < 0.05$ ) with the treatment negative control group and did not have a significant difference ( $P > 0.05$ ) with the treatment group 50 mg/kgbw dose of *Citrus sinensis* peel extract, the treatment group 100 mg/kgbw dose of *Citrus sinensis* peel extract, the treatment group 200 mg/kgbw dose of *Citrus sinensis* peel extract. The treatment group 50 mg/kgbw dose of *Citrus sinensis* peel extract, the treatment group 100 mg/kgbw dose of *Citrus sinensis* peel extract, the treatment group 200 mg/kgbw dose of *Citrus sinensis* peel extract had significant difference ( $p < 0.05$ ) with the negative control.

Gentamicin is a aminoglycoside class antibiotic used against Gram-negative bacterial infections. Gentamicin can cause renal damage and dysfunction which marked by elevation of serum creatinine and urea level (Adil *et al.*, 2016).

The mechanism of gentamicin caused nephrotoxicity was gentamicin-induced the apoptosis as well as necrosis of the tubular epithelial cell and it might also trigger by the predisposing factor such as ischemia of the renal parenchyma. The apoptosis and acquires of

necrosis caused by the cell's ATP reserve drops (Novoa *et al.*, 2011).

*Citrus sinensis* peel extracts were rich in flavonoids and were used as an anti-hyperlipidemia, antidiabetic, anti-inflammatory and antioxidant (Donna *et al.*, 2014). *Citrus sinensis* peel can induced endogenous antioxidant in the body such as superoxide dismutase (SOD) and glutathione (GSH). Where SOD plays a role in counteracting free radicals. Increasing the production of superoxide (-O) that was released from mitochondria due to the toxicity of gentamicin will be bind by SID in the body become  $H_2O_2$  which is more stable and less toxic (Pepe *et al.*, 2018).

#### Histopathology Results of Kidney Organ

From this study found a change in the histological structure of the kidney in the form of glomerular atrophy, changes in tubular lumen and necrosis. The result can be seen at Table IV and Figure 3.

SOD and CAT levels increased in the glandular tissue of mice given 70% ethanol extract of *Citrus sinensis* peel indicating a protective effect against acetic acid induced gastric ulcer (Geetha

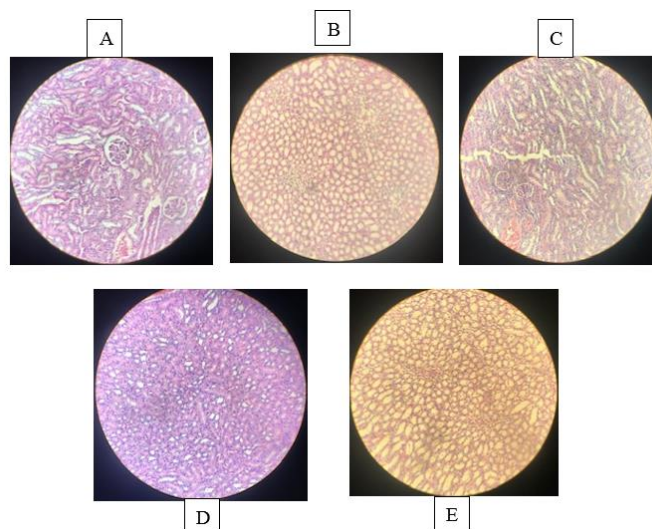


Figure 3. Histopathology Results of Kidney Organ

Note: (A) Negative control; (B) Positive control; (C) Treatment group (*Citrus sinensis* peel extract 50 mg/kgbw); (D) Treatment group (*Citrus sinensis* peel extract 100 mg/kgbw); (E) Treatment group (*Citrus sinensis* peel extract 200 mg/kgbw)

*et al.*, 2010). *Citrus sinensis* peel extract for 14 days in mice can restore GSH levels in blood, liver, and kidneys induced by CC14. SOD, CAT and GSH levels were stable in the body because of the protective effects of reactive metabolites produced by toxicity (Lavanya *et al.*, 2012).

## CONCLUSION

Increasing dose of *Citrus sinensis* peel extract from a dose of 50 mg/kgBW, 100 mg/kgBW and 200 mg/kgBW showed an increase in nephroprotective activity against male white rats induced by gentamicin. The effective dose of *Citrus sinensis* peel extract as nephroprotective is at 200 mg/kgBW dose with serum urea level  $43.33 \pm 2.51$  mg/dl and serum creatinine level  $0.4 \pm 0.02$  mg/dl which shows a significant difference ( $p < 0.05$ ) from negative control and did not show any damage to kidney tissue in tissue histopathology examination.

## REFERENCES

Adil, M., Kandhare, A.D., Dalvi, G., Ghosh, P., Venkata, S., Raygude, K.S. & Bodhankar, S.L. 2016. 'Ameliorative effect of berberine against gentamicin-induced nephrotoxicity in rats via attenuation of oxidative stress, inflammation, apoptosis and mitochondrial dysfunction', *Renal Failure*. 38. 996-1006.

Bhusan, S.H., Ranjan, S.S. Subhangankar, N., Rakesh, S. & Amrita B. 2012. 'Nephroprotective activity of ethanolic extract of

*Elephantopus Scaber* leaves on albino rats', *International Research Journal of Pharmacy*. 3. 246-250.

- Donna, L.D., Iacopetta, D., Capello, A.R., Gallucci, G., Martello, E., Fiorillo, M., Dolve, V. & Sindona, G. 2014. 'Hypocholesterolaemic activity of 3-hydroxy-3-methyl-glutaryl flavonones enriched fraction from bergamot fruit (*Citrus bergamia*): "in vivo" studies. *Journal of Functional Foods*. 7. 558-568.
- Dosoky, N.S. & Setzer, W.N. 2018. 'Biological activities and safety of *Citrus* spp. essential oils', *Int. J. Mol. Sci*. 19. 1-25.
- Etebu, E. & Nwauzoma, A.B. 2014. 'A Review on Sweet Orange (*Citrus Sinensis* L. Osbeck): Health, Diseases and Management. *American Journal of Research Communication*. 2. 33-70.
- Favela-Hernandez, J.M.J., Gonzalez-Santiago, O., Ramirez-Cabrera, M.A., Esquivel-Ferrino, P.C. & Camacho-Corona, M.D.R. 2016. 'Chemistry and Pharmacology of *Citrus sinensis*', *Molecules*, 21. 1-24.
- Geetha, K.M., Sridhar, C. & Murugan, V. 2010. 'Antioxidant and healing effect of aqueous alcoholic extract of *Rhodymyrtus tomentosa* (Ait.) Hassk. on chronic gastric ulcers in rats', *Journal of Pharmacy Research*. 3. 2860-2862.
- Gelaw, B.K., Tegegne, G.T., Defersha, A.D. & Legese, A. 2014. 'Retrospective drug use evaluation of gentamycin use in Ambo Hospital, Oromia

- Region State, West Showa, Ethiopia', *IJOPP*. 7, 16-22.
- Lavanya, G., Voravuthikunchai, S.P. & Towatana, N.H. 2012. 'Acetone extract from *Rhodomyrtustomentosa*: a potent natural antioxidant', *Evidence-Based Complementary and Alternative Medicine*. 2012.1-8.
- Novoa, J.M.L., Quiros, Y., Vicente, L., Morales, A.I. & Hernandez, F.J.L. 2011. 'New insights into the mechanism of aminoglycoside nephrotoxicity: an integrative point in view', *International Society of Nephrology*. 79. 33-45.
- Pandey, A. & Tamta, S. 2016. 'Efficient micropopagation of *Citrus sinensis*(L.)Osbeck from cotyledonary explants suitable for the development of commercial variety', *African Journal of Biotechnology*. 15. 1806-1812.
- Pepe, G., Sommela, E., Cianciarulo, D., Ostacolo, C., Manfra, M., Sarno, V.D. *et al.* 2018. 'Polyphenolic extract from tarocco (*Citrus sinensis*L. Osbeck) clone "Lempso" exerts anti-inflammatory and antioxidant effects via NF- $\kappa$ B and Nrf-2 activation in murine macrophages', *Nutrients*. 10. 1-12.
- Randjelovic, P., Veljkovic, S., Stojiljkovic, N., Sokolovic, D. & Illic, I. 2017. 'Gentamicin nephrotoxicity animals: current knowledge and future perspectives', *EXCLI Journal*. 16. 388-399.
- Tahir, E.E., Shaddad, S.A., Muddathir, A.K. & Agabna N.M.E. 2016. 'Nephro-protective effect of *Acica Senegal* against gentamycin-induced renal damage in rats', *World Journal of Pharmaceutical Research*. 5. 294-303.
- Udupa, V. & Prakash, V. 2019. 'Gentamicin induced acute renal damage and its evaluation using urinary biomarkers in rats', *Toxicology Reports*. 6. 91-99.
- Yarijani, Z.M., Najafi, H. & Madani, S.H. 2015. 'Protective effect of crocin on gentamicin-induced nephrotoxicity in rats', *Irian J Basic Med Sci*. 19. 337-343.